

Candidate name: _____

Department of
Emergency Medicine

Princess Alexandra Hospital

FELLOWSHIP TRIAL EXAMINATION
2017.1

WRITTEN EXAMINATION

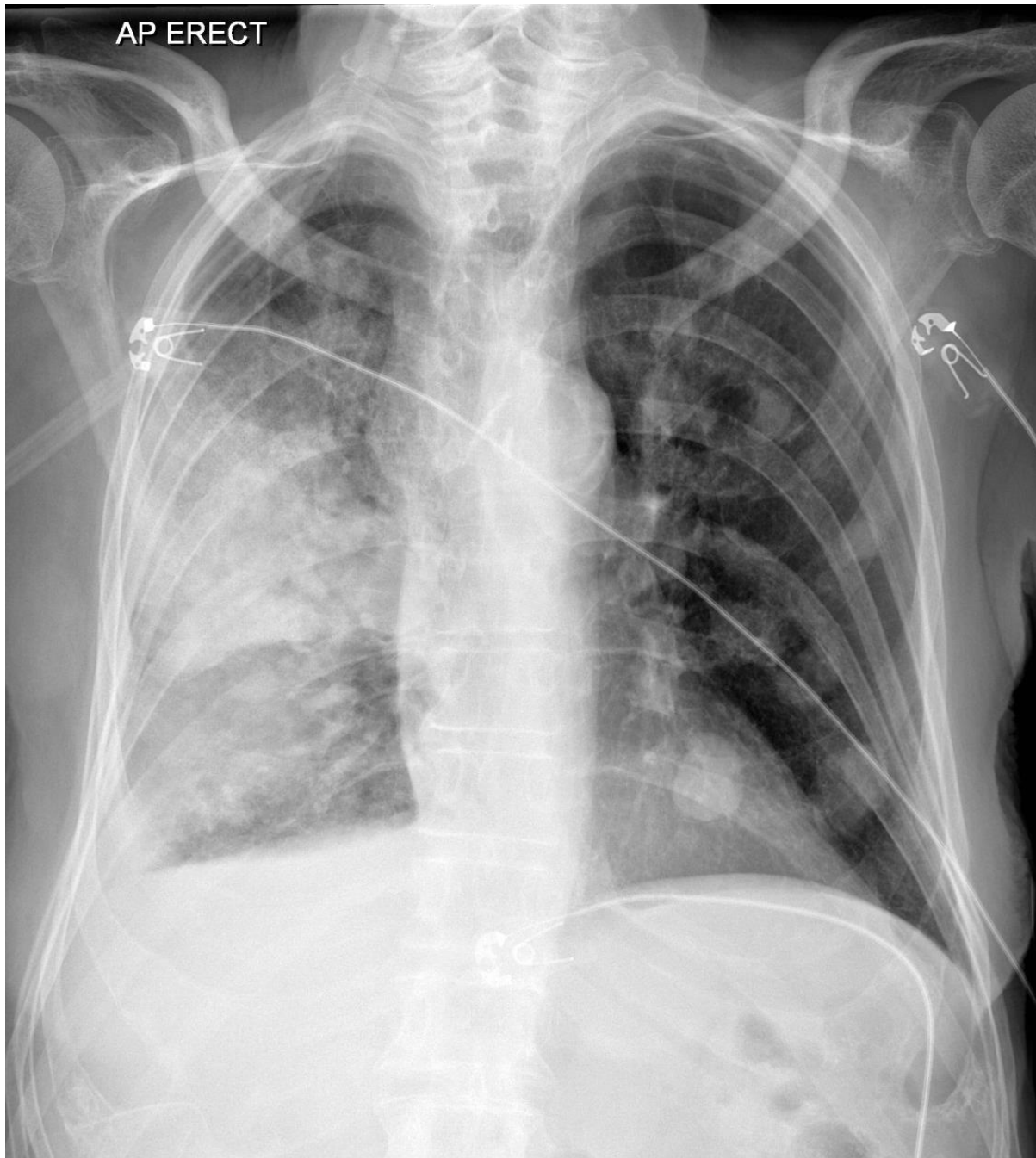
SHORT ANSWER QUESTIONS

PROPS
BOOKLET

Q2

A 78 year old man has been brought to the hospital by ambulance with severe shortness of breath. He has had 2 days of fever and productive cough.

His chest x-ray is shown below.

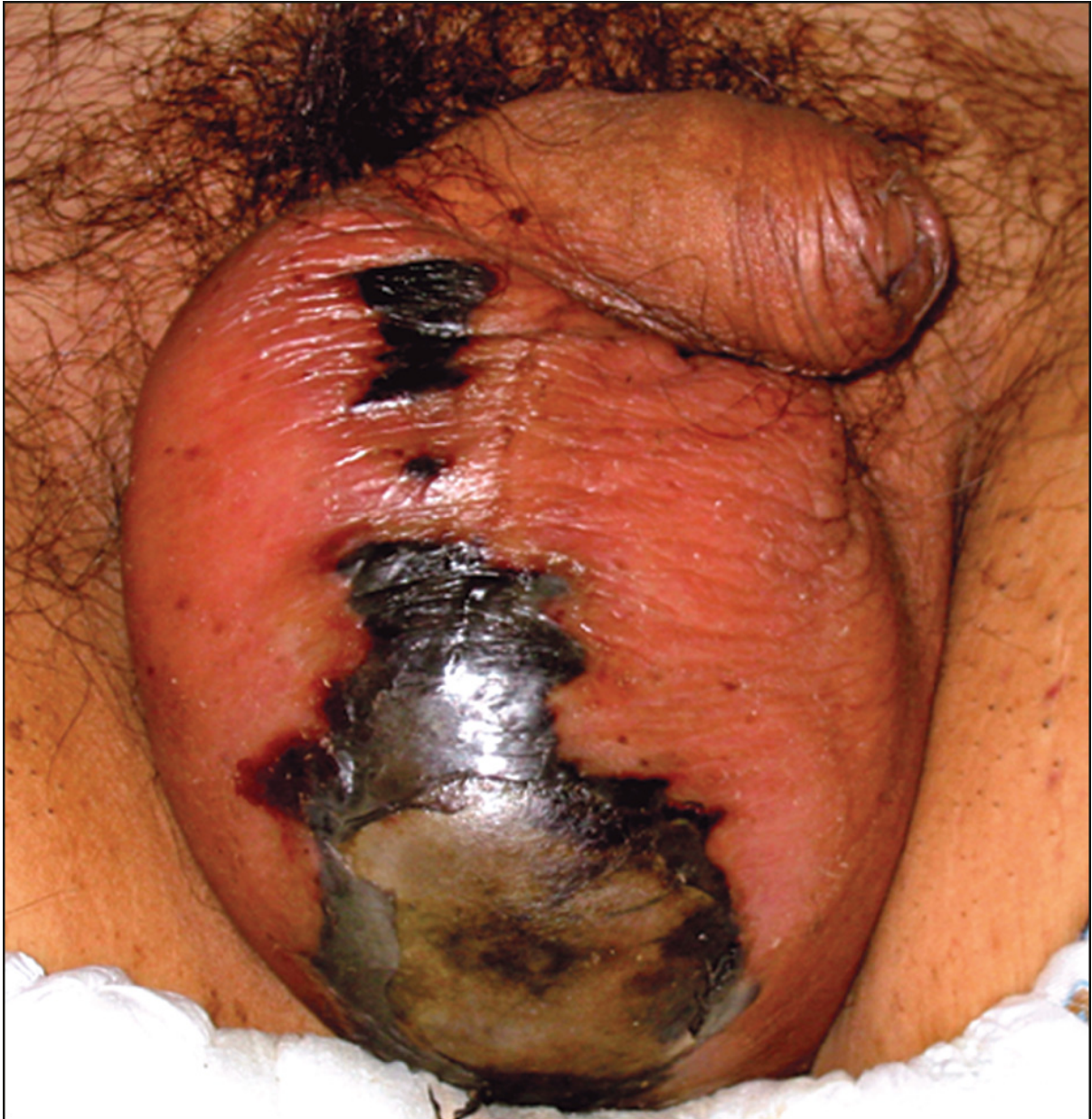

Candidate initials: _____

Q3

A 48 year old 100kg diabetic man has been brought to the ED with severe perineal pain.

A clinical photo is provided below.



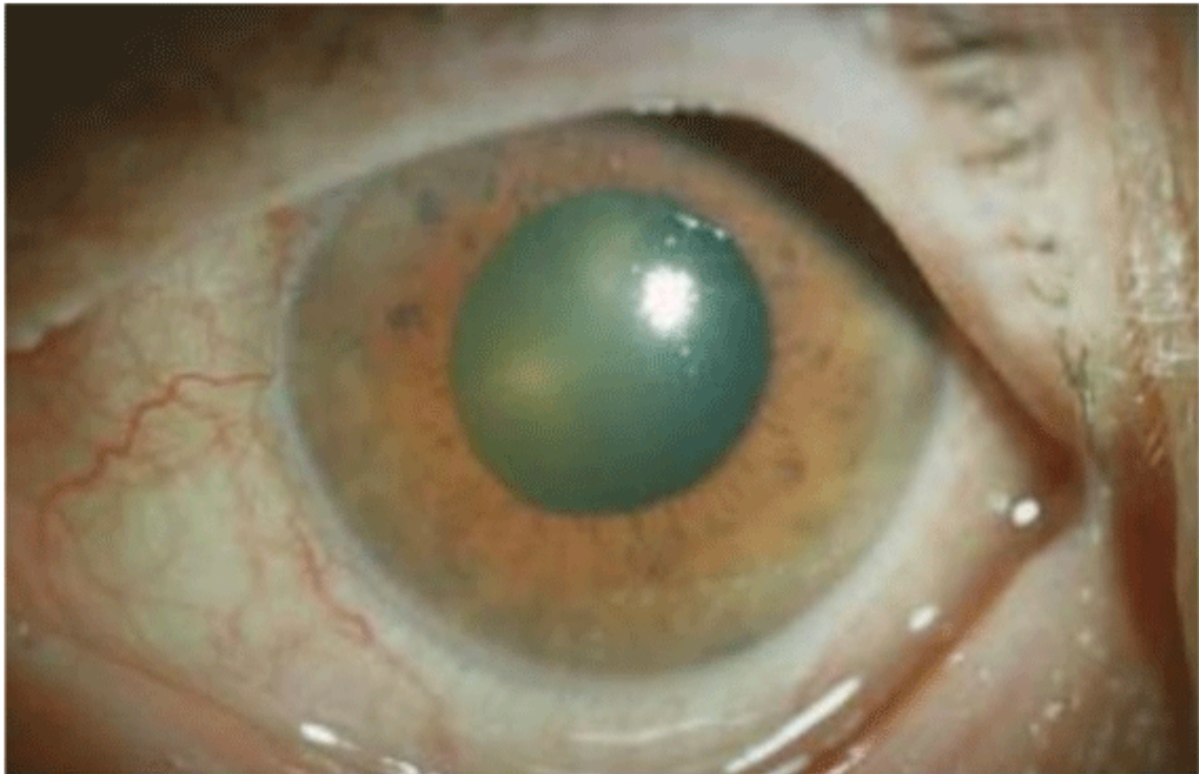
Candidate initials: _____

Q6

A 45 year old woman has presented with an intensely painful right eye of 2 hours duration. Her pain began while she was watching a movie.

She has no known medical history.

A clinical photo is provided below.

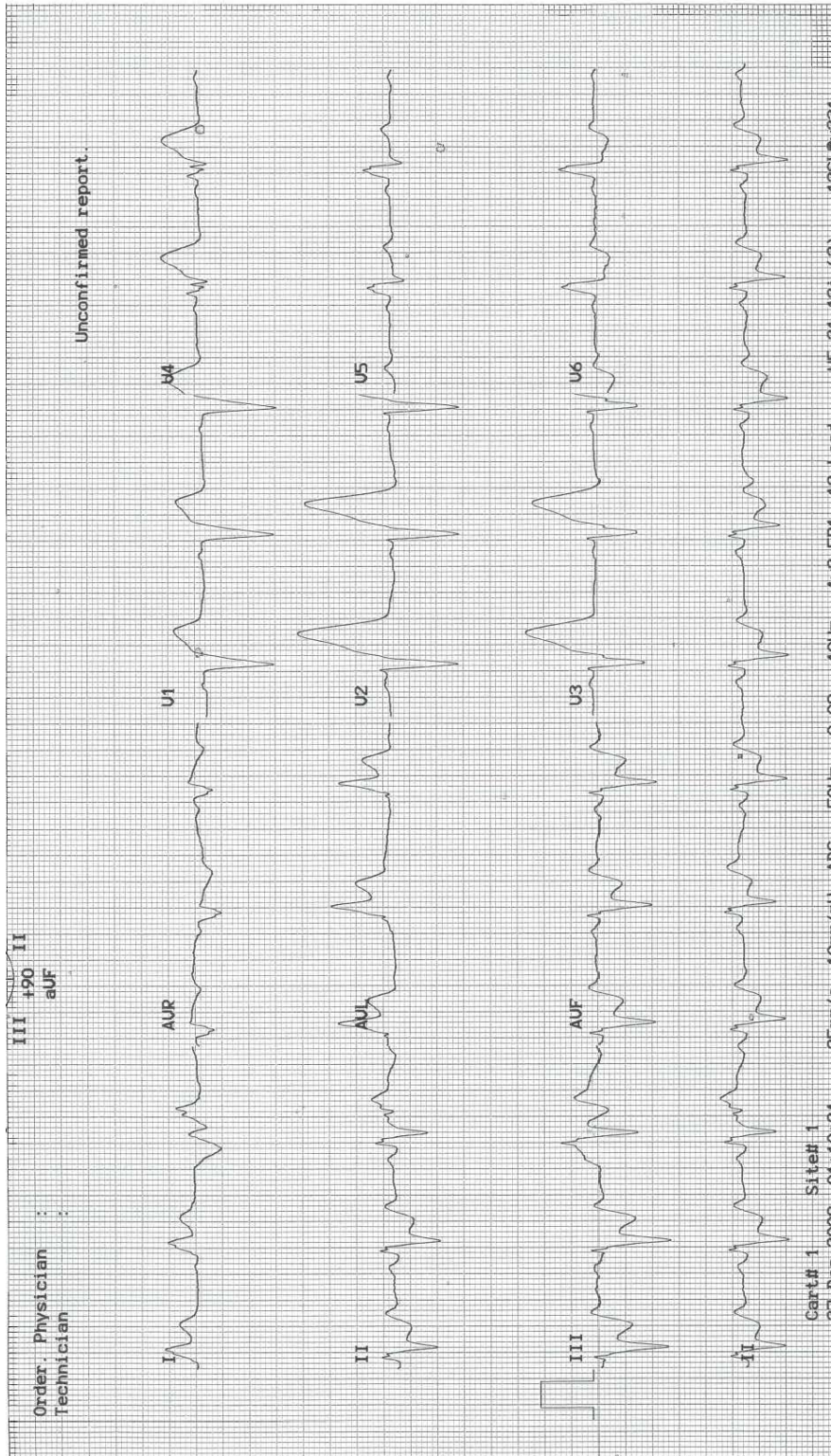


Q7

A 64 year old woman has presented with 3 hours of chest pain.

She has a history of type 2 diabetes mellitus and hypertension.

Her ECG is reproduced below.

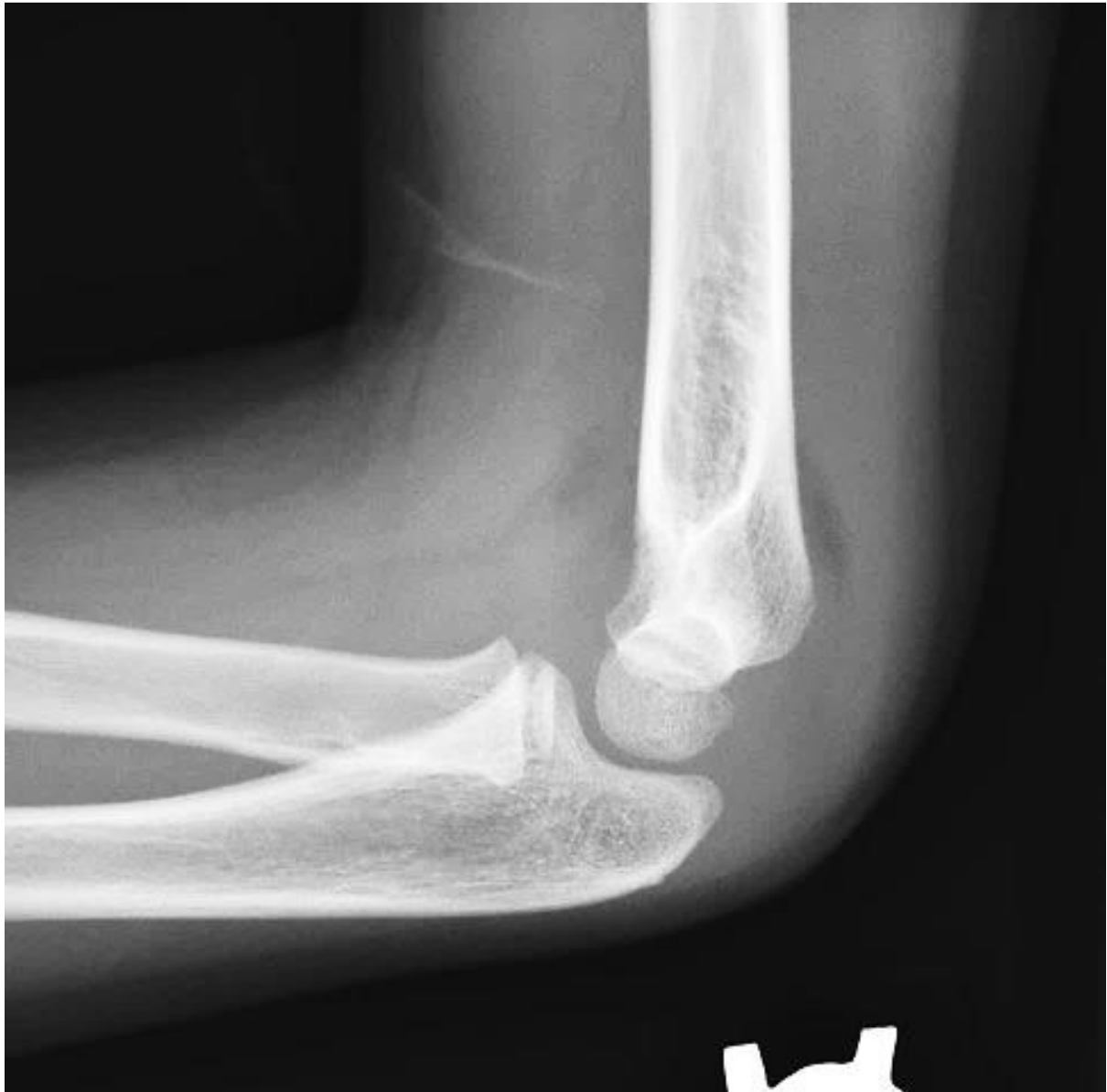

Candidate initials: _____

Q8

A 4 year old boy has been brought to the ED after falling off a couch at home. He has a painful right elbow.

His elbow x-ray is provided below.



Candidate initials: _____

Q 10 (12 min)

A 4 year old boy has been brought to your ED with a 2 day history of increasing vomiting and lethargy.

He has had a venous blood gas taken. The result is provided below.

Venous blood gas

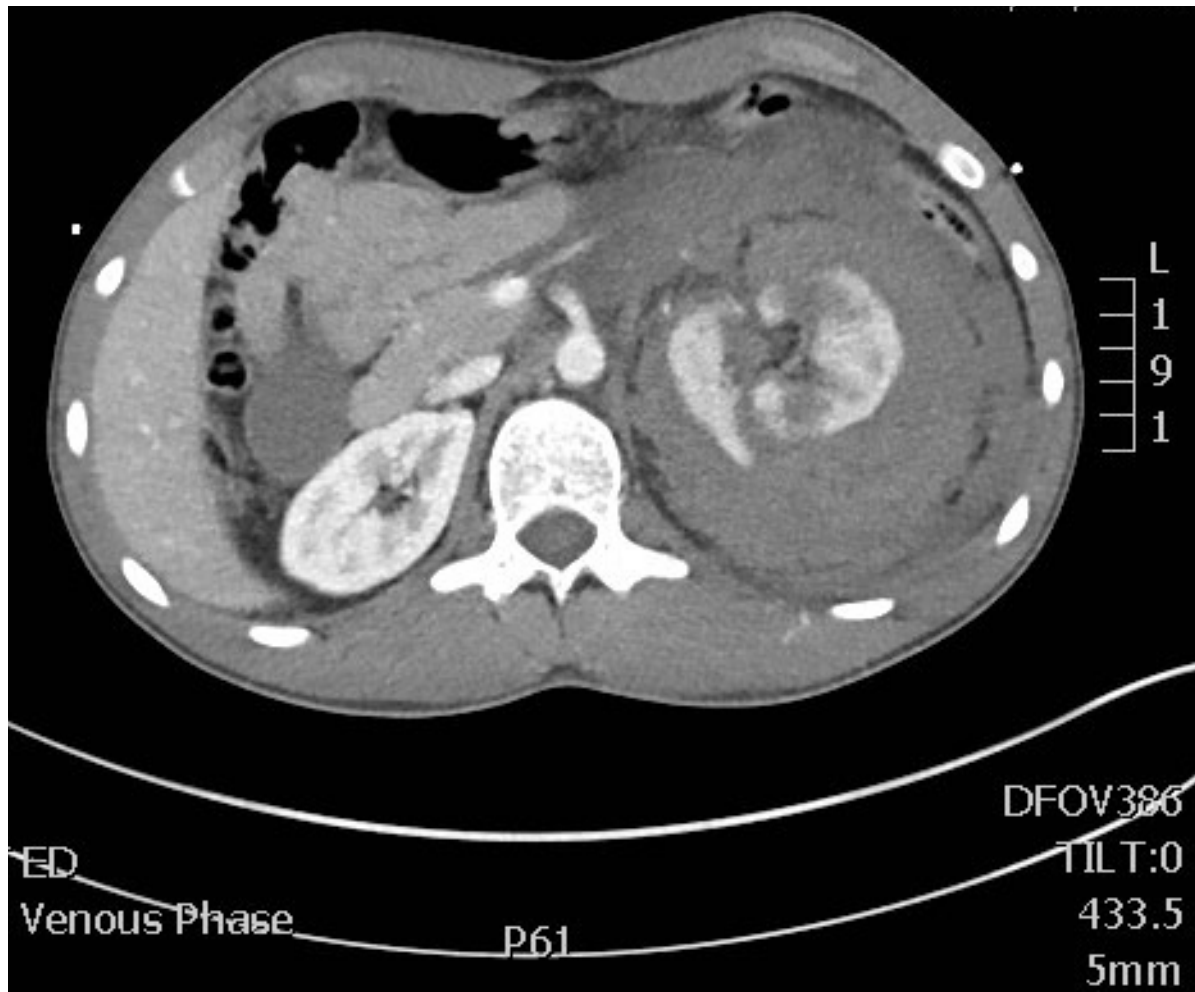pH	7.18		(7.35 – 7.45)
pCO ₂	21	mmHg	(35 – 45)
pO ₂	25	mmHg	(80 – 100)
HCO ₃ ⁻	8	mmol/L	(22 - 32)
BE	-18.5	mmol/L	(-3 - +3)
Na	125	mmol/L	(135 – 145)
K	5.7	mmol/L	(3.5 – 5.0)
Cl	88	mmol/L	(100 – 110)
Glucose	38	mmol/L	(3.0 – 7.8)

Candidate initials: _____

Q12

A 26 year old man has been brought to the ED after falling from a horse.

A CT scan has been performed. One image is provided below.

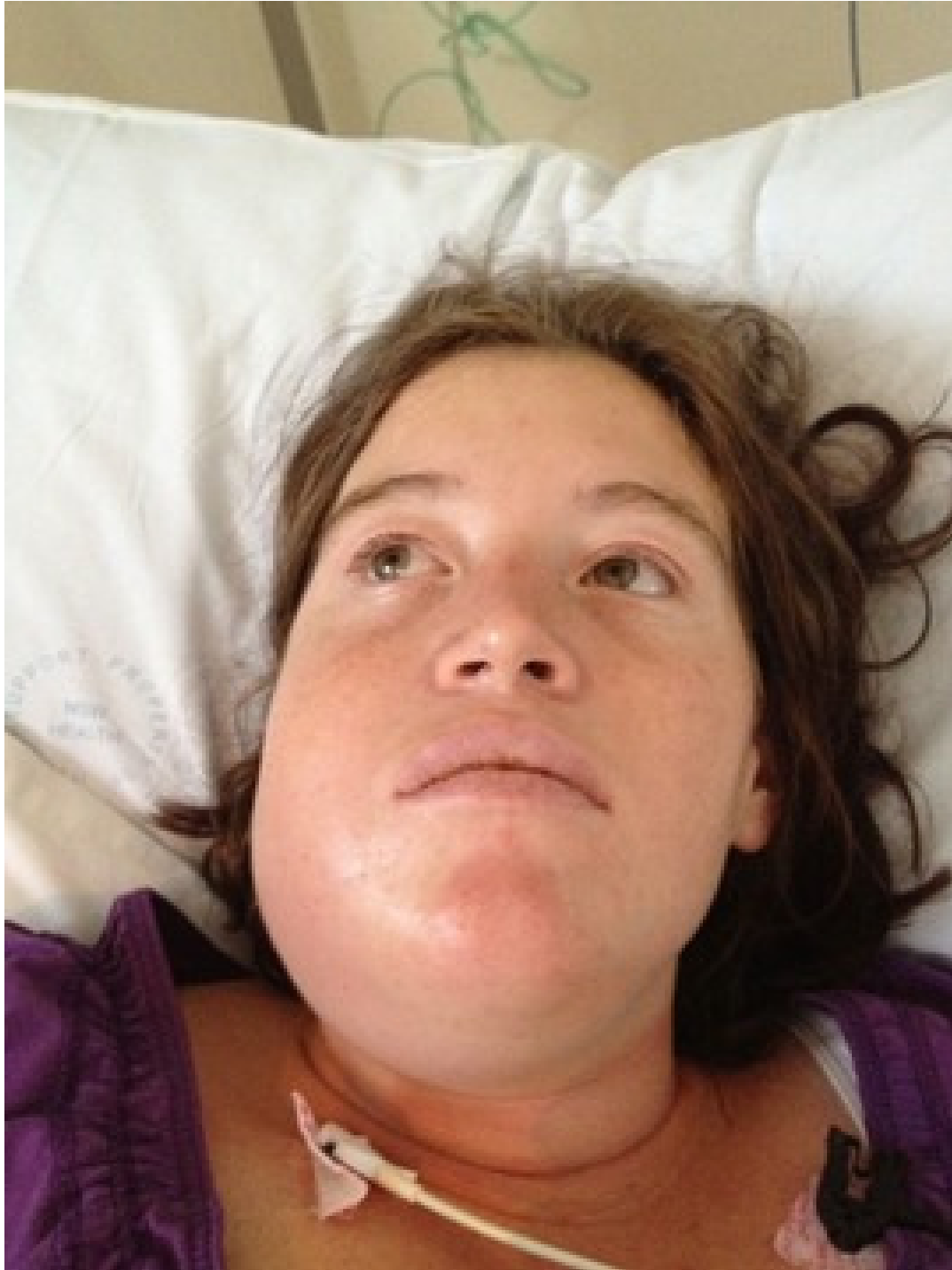


Candidate initials: _____

Q13

A 25 year old woman has presented to the ED with a 3 day history of jaw pain and swelling.

A clinical photo is provided below.

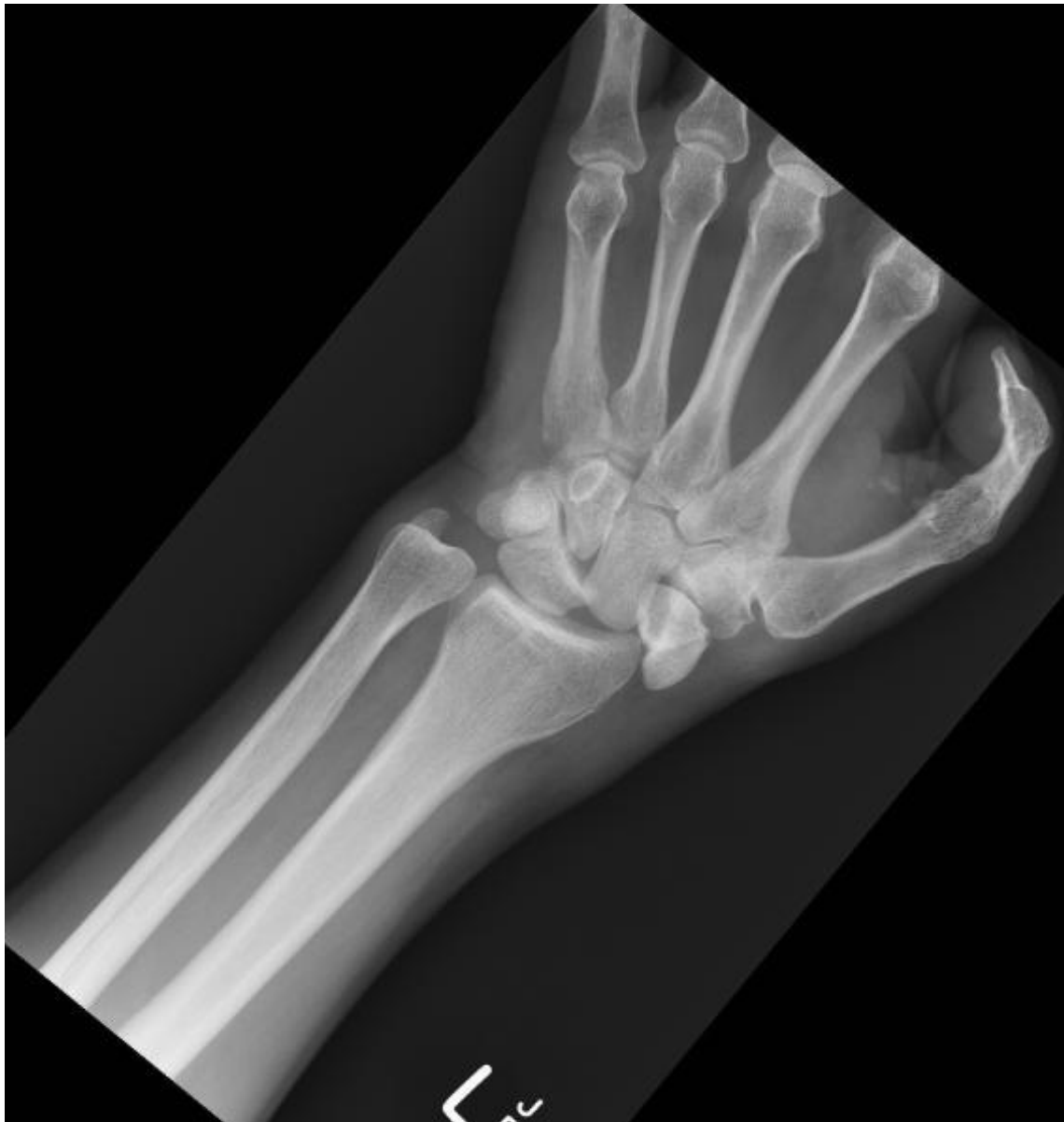

Q16

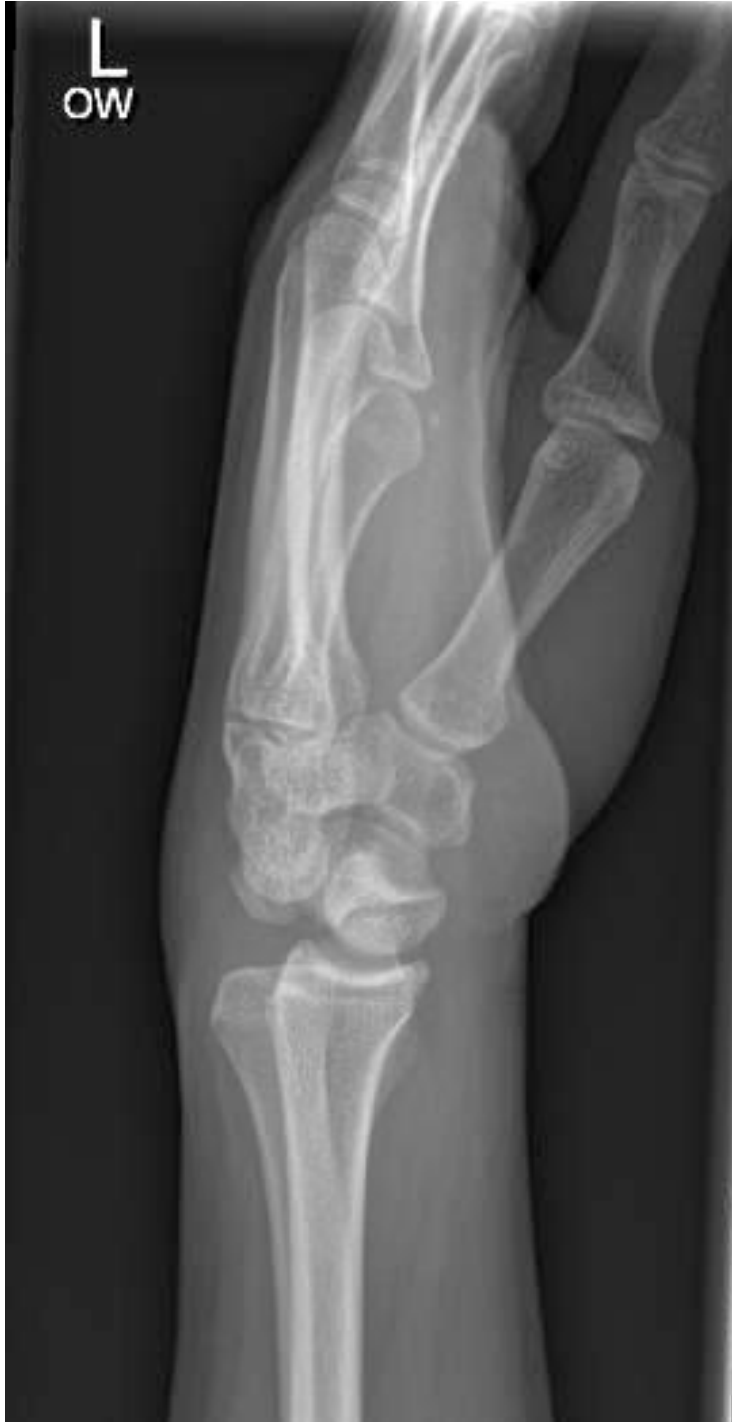A 20 year old man has presented to the ED after falling on to his left hand while playing basketball.

His x-rays are provided below.

*****Two x-rays are provided**



Candidate initials: _____



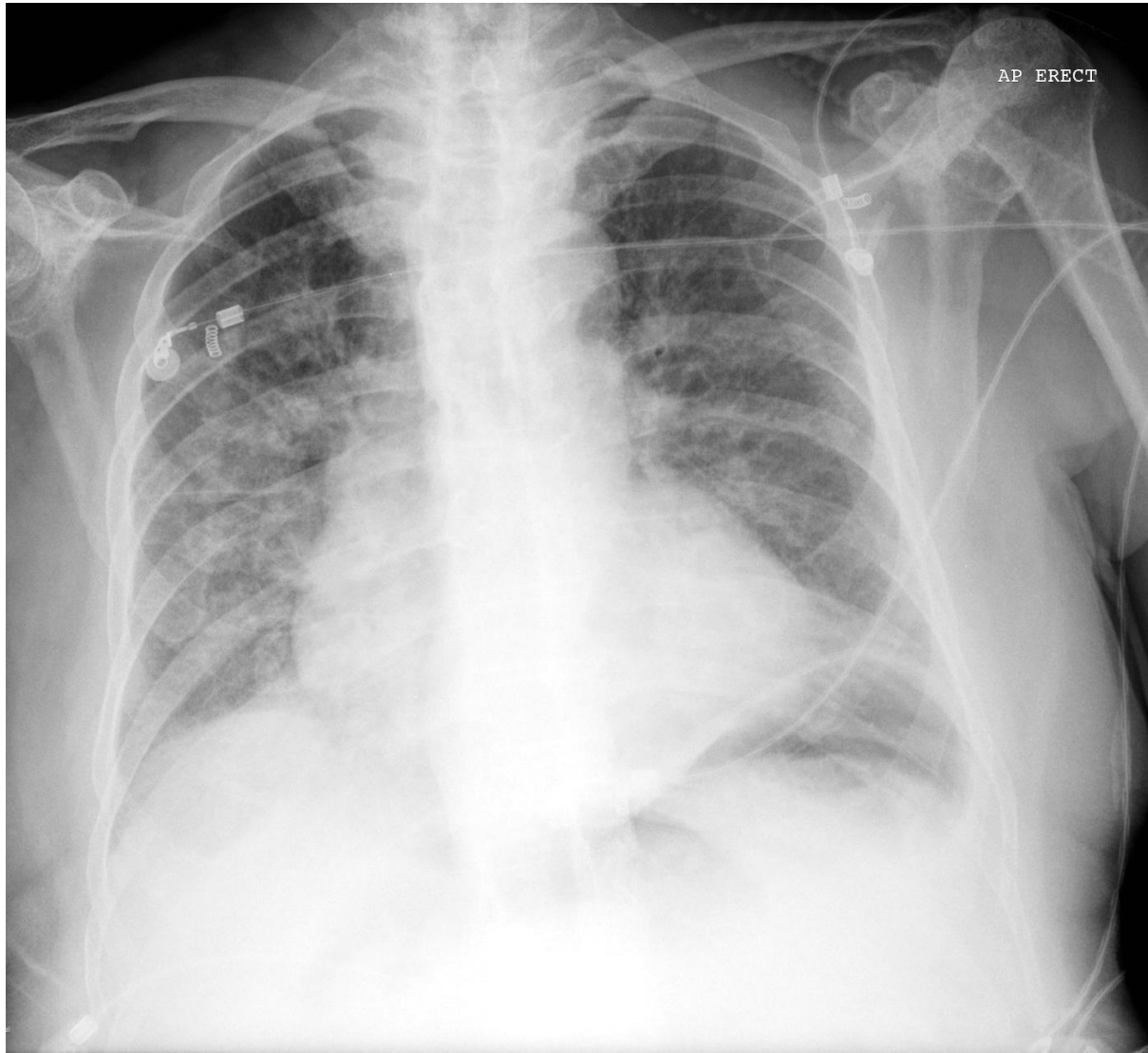
Candidate initials: _____

Q19 (9 min)

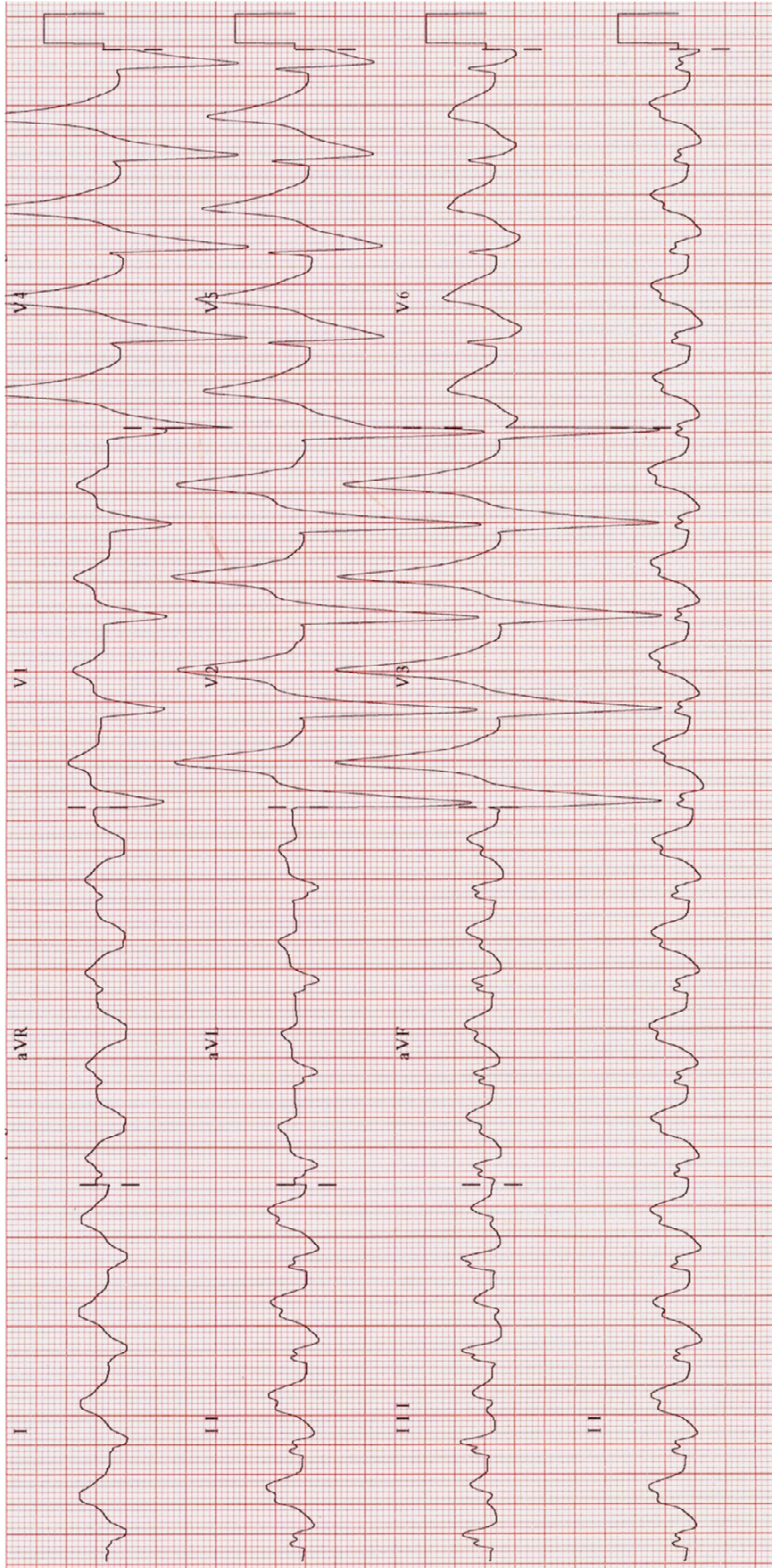
A 55 year old woman has presented to the ED with severe dyspnoea.

Her past medical history includes type 2 diabetes mellitus, hypertension and end-stage renal failure.

Her chest x-ray and ECG are provided below.



Candidate initials: _____



This paper is property of the Princess Alexandra Hospital Emergency Department and should not be distributed or published in any way without written permission

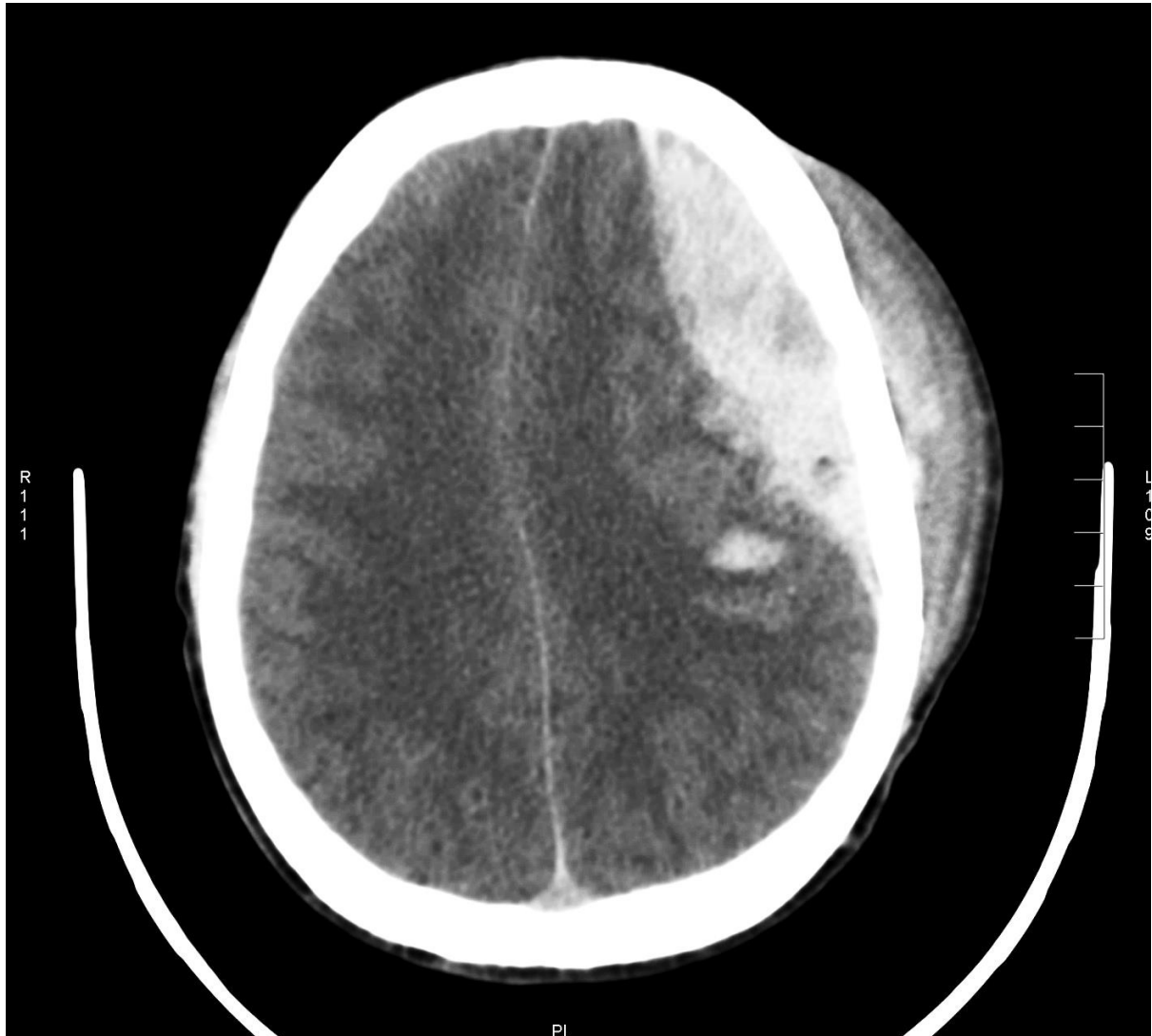
Candidate initials: _____

Q21

A 25 year old man has been brought to the ED after being hit to the head with a beer bottle while at a party.

Assessment reveals an isolated head injury.

A slice from the CT scan of his head is shown below.



Q23

A 25 year old man has presented to ED with 2 days of vomiting associated with progressive weakness and lethargy.

He recently commenced chemotherapy for Non-Hodgkin's Lymphoma.

His vital signs are normal.

His biochemistry profile is shown below.

Biochemistry profile

	Result	Reference range	
Na	131	135 – 145	mmol/L
K	6.6	3.2 - 5.0	mmol/L
Cl	85	95 – 110	mmol/L
HCO ₃	16	20 – 28	mmol/L
Ca	0.97	2.20 - 2.55	mmol/L
Phos	4.4	0.8 – 1.1	mmol/L
LDH	950	220 - 420	
Urate	2.1	0.15 – 0.40	mmol/L
Urea	19	3.0 – 8.0	mmol/L
Creat	321	36 – 73	umol/L

Q27

A 75 year old man has presented to the ED with abdominal pain and distension.

His abdominal x-ray is shown below.

