

OSAQ 1 (14 marks)

An 87 year old lady from home presents after slipping and falling down her stairs. She has neck pain, and no other injuries.

You are concerned about possible spinal cord injury.

Complete the following table detailing signs and mechanism of various spinal cord syndromes (8 marks)

Syndrome	Signs	Mechanism
Central Cord Syndrome	Incomplete paralysis, distal > proximal , arms > legs. Variable reflexes (transmission in central cord is injured, transmission in outer rim is intact but impaired)	Usually hyperextension injury in older patients with cervical spondylosis, cord compressed between osteophytes and intervertebral disc in front and ligamentum flavum behind.
Anterior Cord Syndrome	Lose anterior spinothalamic function (pain and temp), motor impaired. Motor loss or paralysis below level of injury. Dorsal columns relatively intact therefore some joint position, fine touch.	Hyperflexion injury causing bony impaction into cord
Brown Sequard Syndrome	Ipsilateral motor/proprioception loss Contralateral pain and sensation loss Reflexes variable	Penetrating injury

Posterior Cord Syndrome	Uncommon Loss of dorsal column function only	Usually due to penetrating injury
-------------------------	---	-----------------------------------

She has a CT scan performed of her cervical spine

Describe the CT findings (see image in separate book) (2 marks)

Teardrop fracture of C6 , degenerative changes , spinous process fracture c6

On examination you find an incomplete cord injury

List 4 things you can do (apart from spinal immobilisation) as secondary prevention of further injury

(4 marks)

Monitoring of respiratory function, as cervical spine injury

NG tube insertion

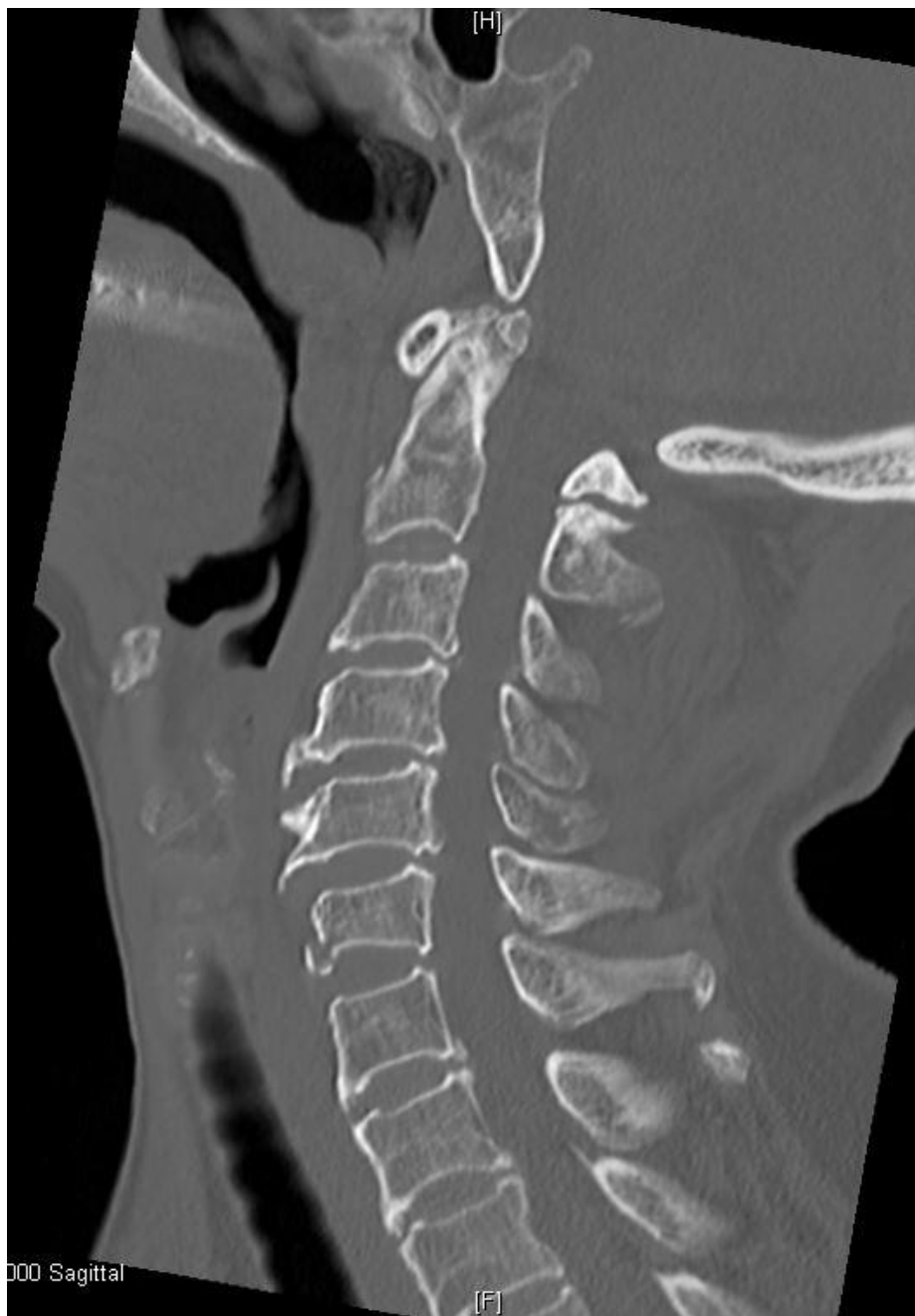IDC placement

Skin protection (air mattress bed)

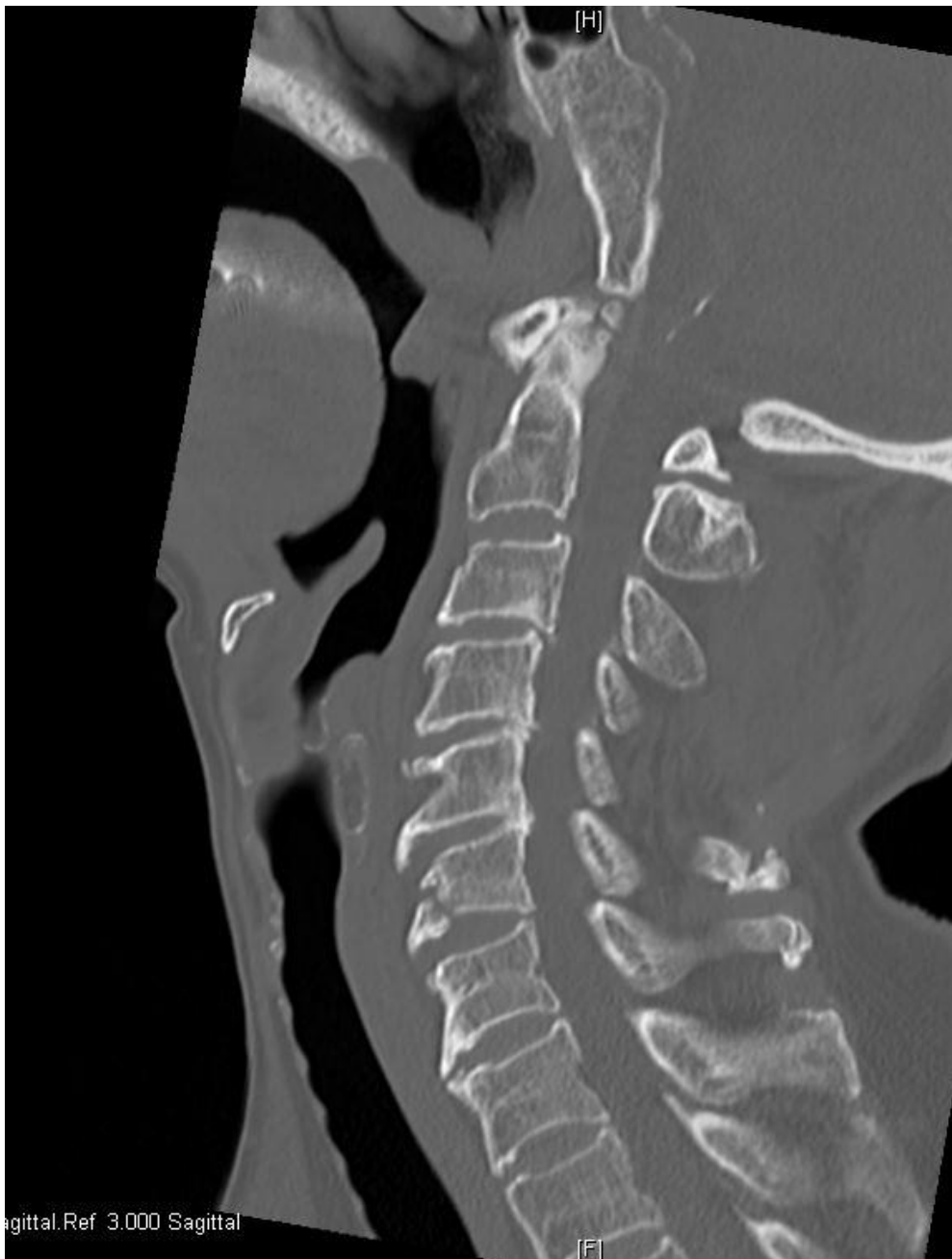Thermal protection (keep pt warm)

Seek and treat other spinal injury

SAQ 1 image 1



SAQ 1 image 2



SAQ 2 (9 marks)

A 4 year old boy with autism presents with his mother having placed a foreign body up his nose. (See image)

He is agitated and unco-operative.

List the three safest methods of removal in this case (3 marks):

Answer – Positive Pressure insufflation (Carer or BVM)
Balloon Catheter extraction – Foley or Fogarty

Sedation and direct instrumentation

Before attempting removal by techniques not involving sedation what steps are necessary in preparation (2 marks)?

Answer must include - Explanation to the child and carer and verbal consent.

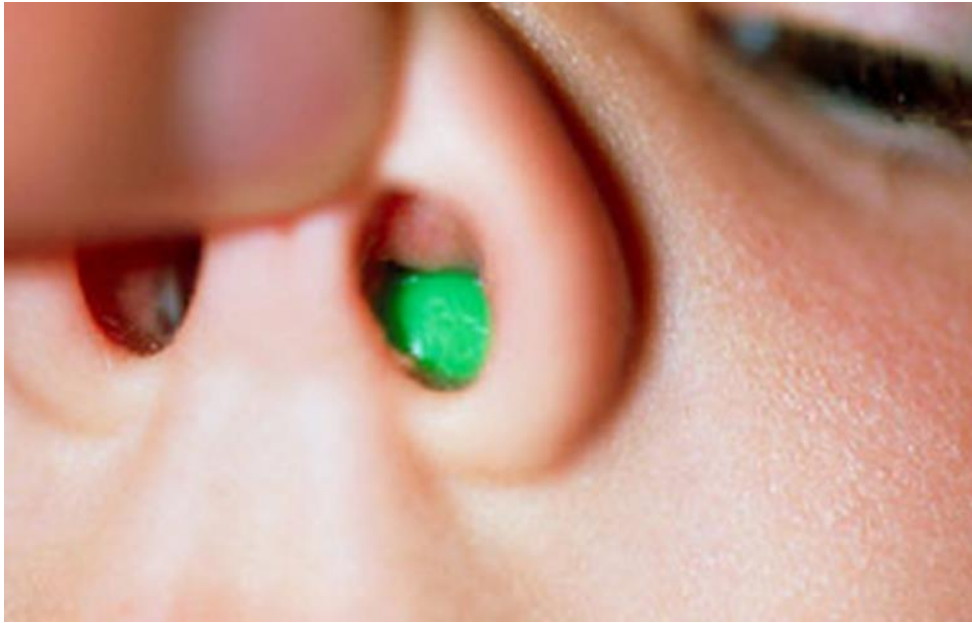Topical application of local anaesthetic vasoconstrictor spray such as Lignocaine Hydrochloride/Phenylephrine.

Due to the child's agitation and lack of co-operation there is a failed attempt at removal of the Foreign Body and it can no longer be visualised. What circumstances would indicate the need for consideration of bronchoscopy (4 marks)?

Answer - Coughing and choking
Stridor
Unilateral wheeze
Hypoxia

Score - 4/4 – lose 2 points for any item left out.

SAQ 2 image



SAQ 3 (12 marks)

A 60 yr old lady presents with vertigo.

In column 1 list 4 important diagnoses to consider in any patient that presents with persistent vertigo.

In Column 2 list the historical features that would suggest each diagnosis.

In Column 3 list the findings on physical examination that would suggest each diagnosis.

Column 1 : diagnosis	Column 2 : historical features	Column 3 : signs on examination
BPPV	Intermittent vertigo, worse on movement, lasts seconds – minutes, but can have ongoing disequilibrium after acute attacks	Normal neurological examination +ve Hallpike test
Vestibular neuronitis/ labyrinthitis	Subacute onset over hours Persistent symptoms Can last several days Can get hearing loss with labyrinthitis	Normal cranial nerve examination +ve head impulse test
Migranous Vertigo	Past history of migraines, now increased frequency with vestibular episodes. Can occur with or without headache.	Diagnosis of exclusion, normal neurological examination
Cerebellar stroke	Hyperacute onset of vertigo Occipital headache Difficulty walking	Ataxia – gait or truncal Cerebellar signs – past pointing/ disdiadochokinesis

	Loss of coordination	Head impulse test negative Bidirectional or vertical nystagmus +ve test of skew
Brainstem CVA	Sudden onset Can get sudden hearing loss also	Cranial nerve signs Hearing loss -ve head impulse test

Marking guide :

Must include stroke/cva in order to score >6/12

Column 1 : worth 0.5 mark

Column 2 : 0.5 mark per feature

Column 3 : : 0.5 marks per sign

Maximum 3 marks per diagnosis.

SAQ 4 (10 marks)

A 15 year old boy has been transferred to your Emergency Department from a rural hospital. He had been given IV benzylpenicillin for a throat infection 48 hours previously.

Describe the appearance of the rash and give a likely differential diagnosis (3 marks)

- a) A widespread erythematous rash with bullous detachment of the epidermis. Scalded skin appearance. Appears to affect at least 40% of body surface area.

Likely toxic epidermal necrolysis.

Differential includes Stevens Johnson Syndrome (rash too widespread however), staphylococcal scalded skin syndrome, erythematous drug reaction, paraneoplastic pemphigus (eg. Lymphoma), erythema multiforme (herpes simplex), erythroderma (no mucosal involvement)

Assuming that the underlying cause is a severe drug reaction, outline how you would grade the severity (2 marks)

The severity and prognosis of SJS/TEN depends upon the amount of skin detachment or "detachable" skin (ie, skin with positive Nikolsky sign). Based upon the percentage of the body surface area (BSA) involved, patients can be classified into three severity groups [1]:

- SJS – skin detachment of <10 percent of BSA
- TEN – skin detachment of >30 percent of BSA
- SJS/TEN overlap – skin detachment of 10 to 30 percent of BSA

Outline your management of the patient (3 marks)

Supportive care is the mainstay of treatment and includes wound care, fluid and electrolyte management, nutritional support, ocular care, temperature management, pain control, and monitoring or treatment of superinfections

Infection control measures, including sterile handling, topical antiseptic agents, and surveillance cultures of possible sites of superinfection, are important components of prevention

Transfer to intensive therapy or burn unit if possible and extensive skin involvement

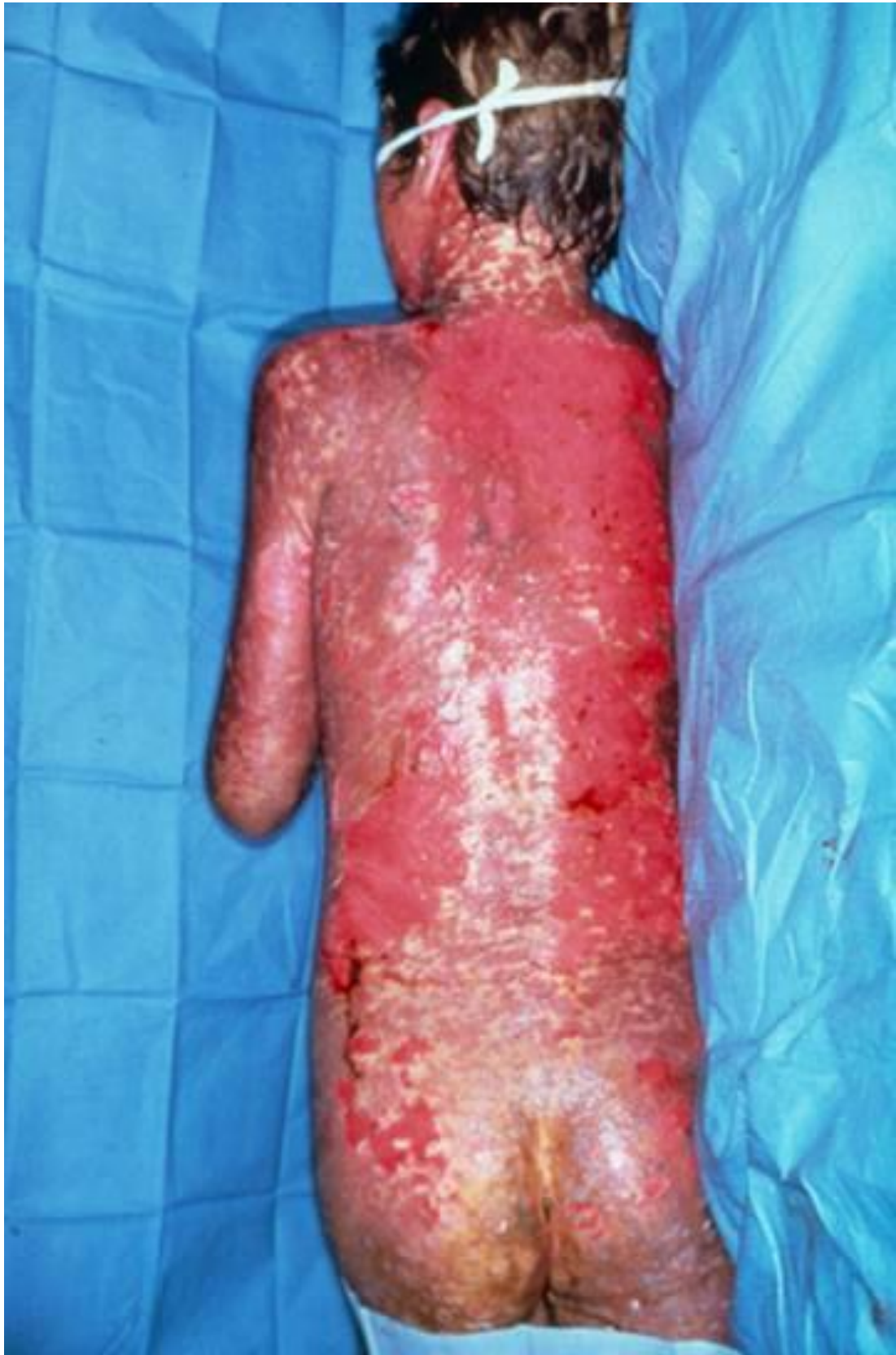What acute complications can develop from this disorder (2 marks)

- c) Massive loss of fluids through the denuded skin, electrolyte imbalance, hypovolemic shock with renal failure, bacteremia, insulin resistance, hypercatabolic state, and multiple organ dysfunction syndrome.

Patients with Stevens-Johnson syndrome/toxic epidermal necrolysis (SJS/TEN) are at high risk of bacterial infection. Sepsis and septic shock, most often caused by *S. aureus* and *P. aeruginosa*, are the main cause of death in these patients.

Pulmonary complications (eg, pneumonia, interstitial pneumonitis) are frequent.

Gastrointestinal complications may result from epithelial necrosis of the esophagus, small bowel, or colon



SAQ 5 (12 marks)

A 45 yr old man presents post falling of pushbike and hitting shoulder into road guardrail after sliding. He has left shoulder pain and no other injuries.

Describe the attached xrays and your diagnosis (2 marks)

Lightbulb appearance of humeral head

Posterior shoulder dislocation

No fracture evident

Describe your method of managing this injury (4 marks)

Analgesia, closed reduction attempt under procedural sedation

Axial traction in line with humerus, gentle pressure on the posteriorly displaced head and slow external rotation.

If reduction fails then OT for reduction under GA

In what position would you immobilise this joint once the injury has been managed in ED? (2 marks)

Immobilise in external rotation with slight abduction

Name the COMMON complications of this injury (2 marks)

Fractures of glenoid rim, greater tuberosity, lesser tuberosity, and humeral head

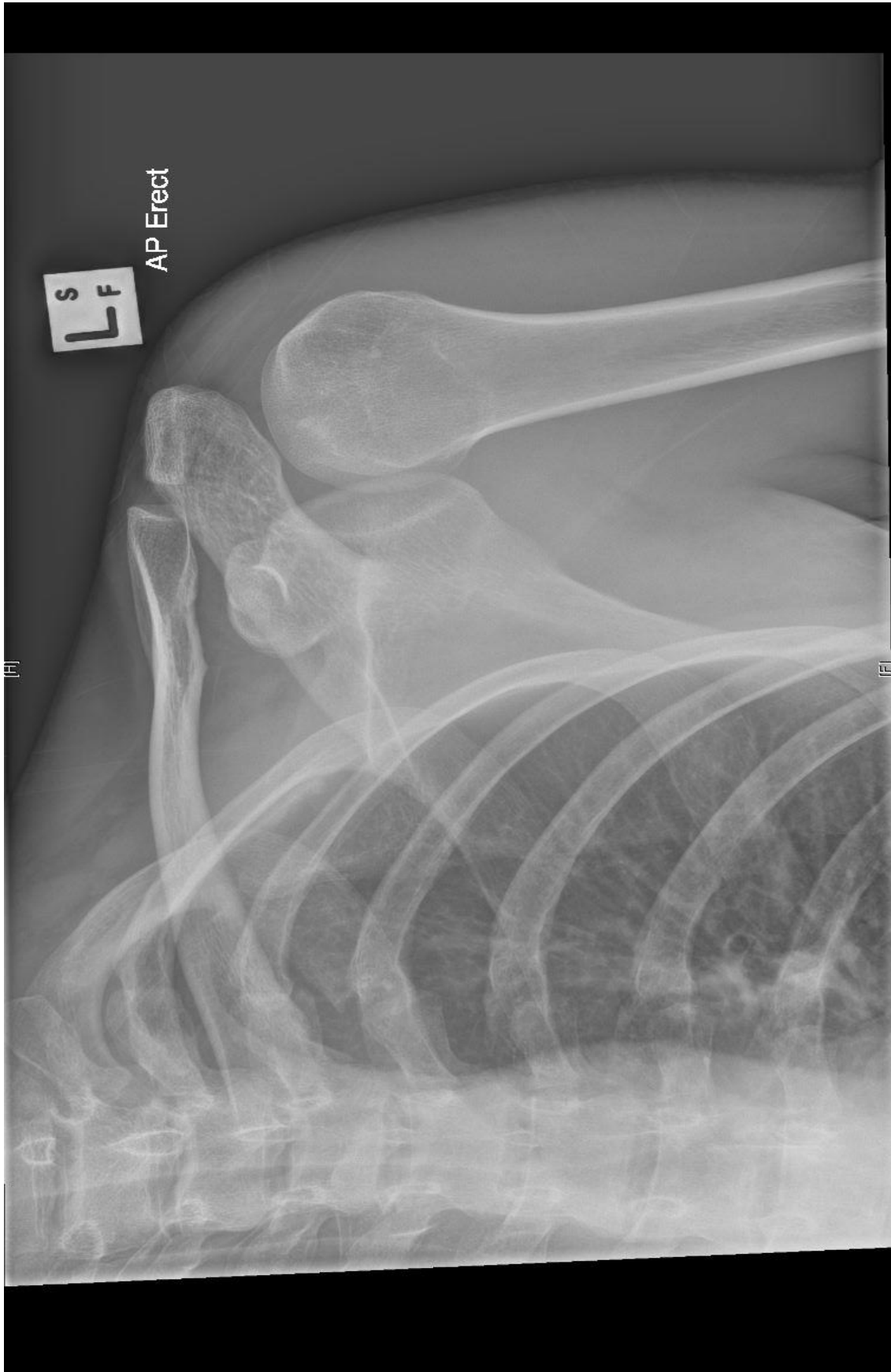30% recurrent dislocations (and these can predispose to degenerative changes)

Name 2 UNCOMMON complications that can occur (2 marks)

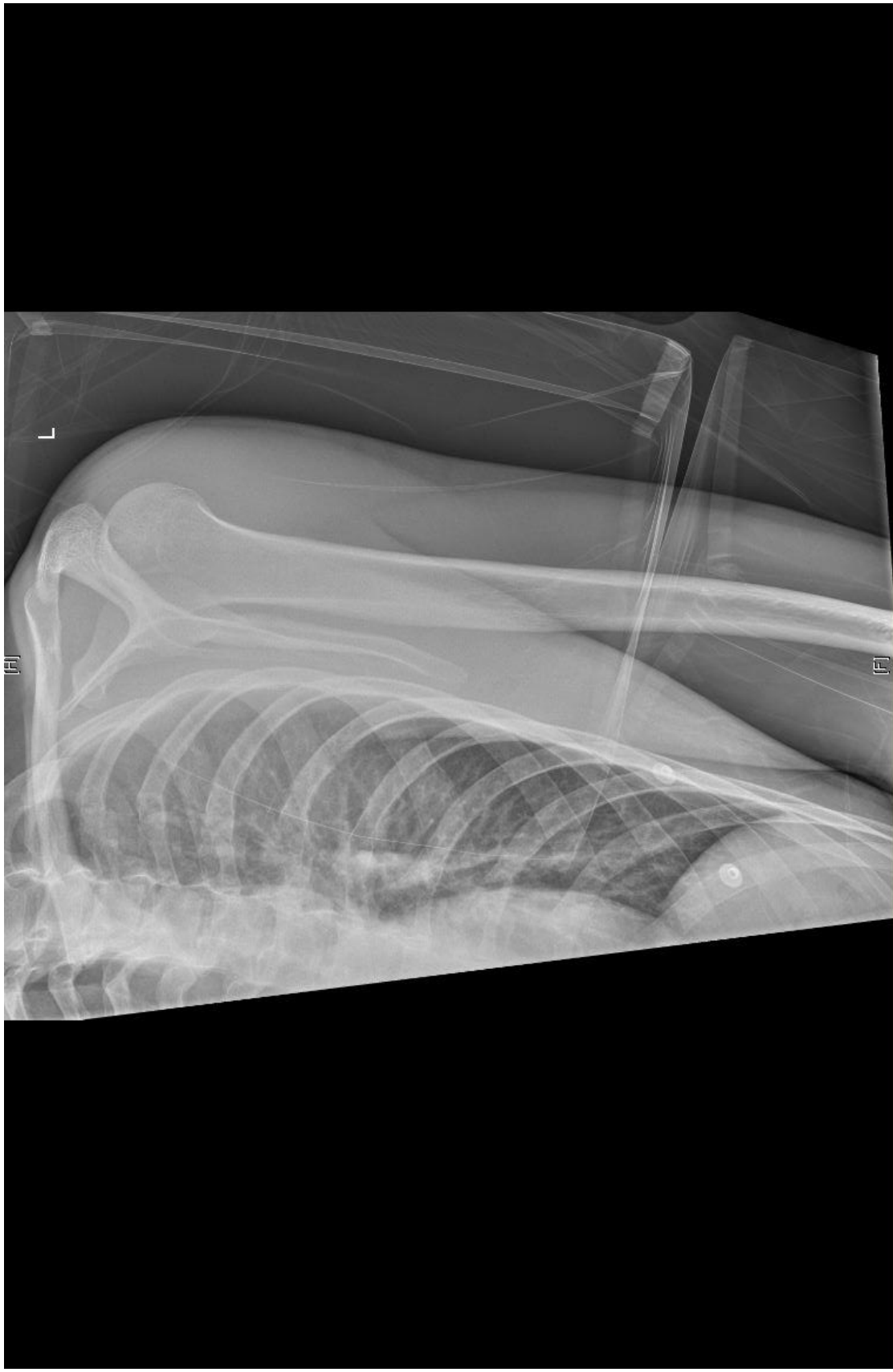Subscapularis muscle avulsion from insertion site on lesser tuberosity

neurovascular injuries uncommon due to the anterior location of the neurovascular bundle.

SAQ 5 image



SAQ 5 image



SAQ 6 (11 marks)

A 38 yo female presents with BP 220/125 and a headache.

Define Hypertensive emergency (1 mark)

Systolic >180mmHg or diastolic >110mmHg associated with evidence of end organ damage

List 6 end organs that might be damaged from severe hypertension and at least one clinical manifestation that you might find on history taking, examination and the appropriate investigation. Name the medication of choice for management of that (6 marks)

<i>Organ</i>	<i>Symptom or sign</i>	<i>Investigation</i>
<i>Heart</i>	<i>CCF</i> <i>Chest pain</i>	<i>CXR</i> <i>ECG</i>
<i>Vascular - aorta</i>	<i>Chest pain</i> <i>BP disparity between arms</i> <i>syncope</i>	<i>CT aortogram</i> <i>CXR</i>
<i>kidney</i>	<i>Nausea, vomiting</i> <i>Reduced urine output</i> <i>polyuria</i>	<i>EUC's</i> <i>U/A for proteinuria</i>
<i>Eye/retina</i>	<i>Blurred vision</i>	<i>Fundoscopy with flare or papilloedema</i>
<i>brain</i>	<i>Headache</i> <i>Syncope</i> <i>Focal neurological signs</i>	<i>CT brain</i>
<i>O&G</i>	<i>Headache</i> <i>Increased reflexes</i>	<i>U/A</i> <i>Uric acid</i> <i>pregnancy</i>

List 2 classes of medication, 2 examples of that class and the dose that can be used for the treatment of hypertensive emergencies. (4 marks)

Class of medication	example	Dose & frequency of treatment
Beta blockers	Metoprolol	5mg IV every 5 mins
	esmolol	0.5-1mg/kg bolus then infusion 50-300mcg/kg/min
vasodilator	Hydralazine	5-20mg IV every 30minutes
	SNiP or GTN	SNiP 0.25-10mcg/kg/min infusion GTN 50mg in 500ml commence 5mls/hr & titrate – 50-200mcg/kg/min

SAQ 7 (11 marks)

A 3yo boy presents to the ED with wheezing and SOB for 2/7. His mother feels that his symptoms are getting progressively worse. His observations are: RR 40, BP 90/50, HR 150 and Sats 92% RA.

List 6 causes of wheezing in a child and 2 historical features that may support that diagnosis. (6 marks)

Cause of wheezing	2 features on history
<i>asthma</i>	<i>May have family history of asthma</i> <i>Nocturnal cough</i> <i>History atopy</i> <i>History that may be of months or years</i>

<p><i>Infection eg RSV</i></p>	<p><i>Fever</i></p> <p><i>Cough, runny nose</i></p> <p><i>Other family members sick</i></p> <p><i>Acute onset</i></p>
<p><i>Inhaled FB</i></p>	<p><i>Choking episode</i></p> <p><i>Sudden onset</i></p> <p><i>Missing toy</i></p>
<p><i>Allergic reaction</i></p>	<p><i>Associated rash</i></p> <p><i>Known allergen exposure</i></p> <p><i>Associated angioedema</i></p>
<p><i>Cardiac failure</i></p>	<p><i>Known cardiac disease</i></p> <p><i>SOB with feeding</i></p> <p><i>SOB at night or with lying down</i></p> <p><i>Ankle/sacral oedema</i></p> <p><i>Failure to thrive</i></p>
<p><i>reflux</i></p>	<p><i>Difficulty with feeding</i></p> <p><i>Complains of pain after or during feeding</i></p> <p><i>Nocturnal cough</i></p> <p><i>Bad breath</i></p> <p><i>Early cavities, esp to back teeth</i></p>

List 3 abnormalities seen on the chest xray (see image)(2 marks)

Collapse of right upper lobe

Consolidation of right upper lobe

Raised right hemidiaphragm

Over the course of his time in ED, RR 50, increased work of breathing, sats 89% on 6L O₂, T37.4 and wheezing only on the right upper side. List 4 management priorities. (2 marks)

Oxygen via HFNP or PEEP

IVF

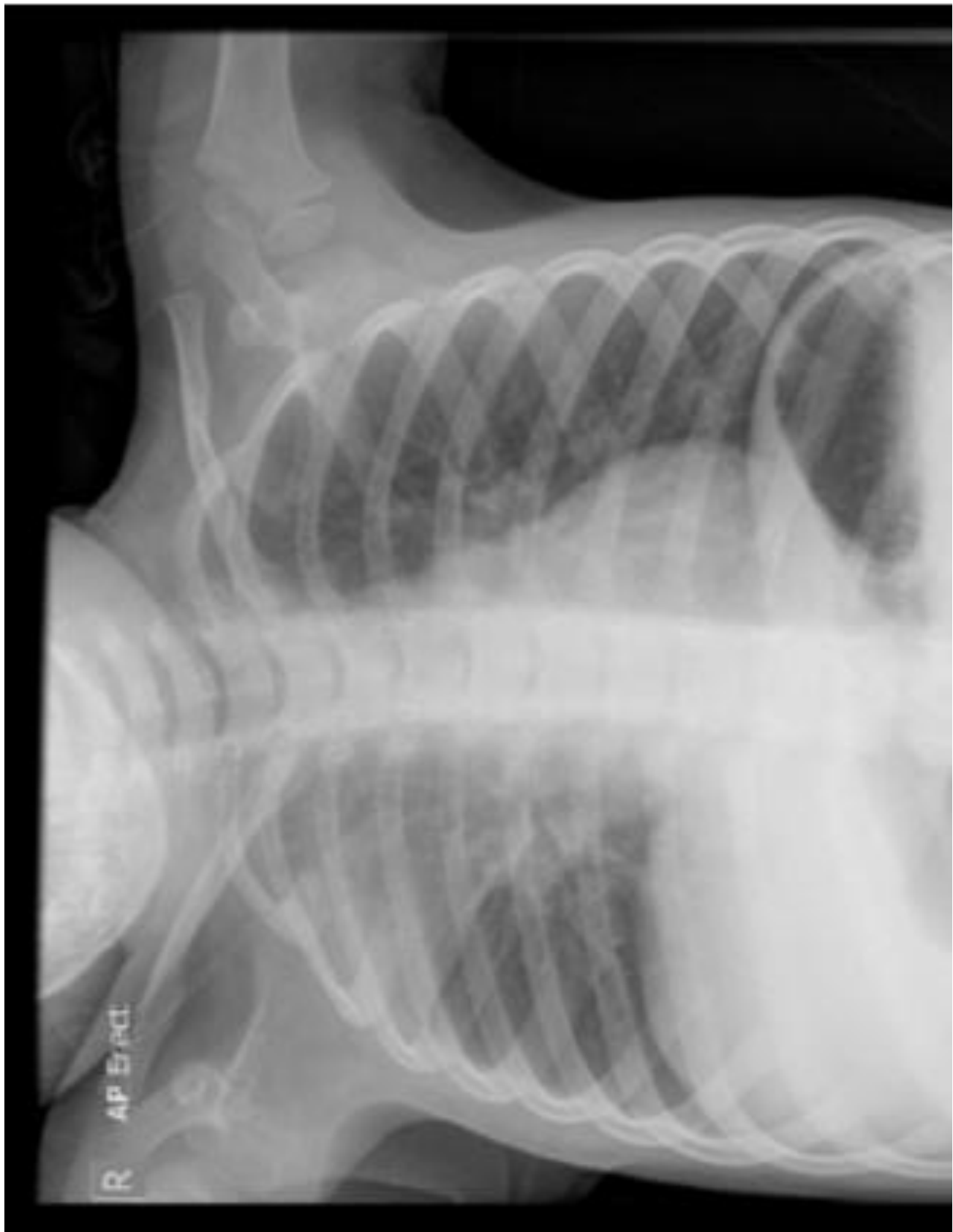Trial of bronchodilator

Organise bronchoscopy

What is the most likely diagnosis? (1 mark)

Inhaled foreign body

SAQ 7 image



SAQ 8 (12 marks)

A 52 year old judo exponent presents to you with a laceration and swelling to his left pinna. (see image)

Describe the injury (2 marks)

Answer –

- A) Auricular haematoma to the right pinna with small associated superficial skin tear. There is no apparent involvement of the tragus or of the external auditory meatus or canal. The overlying skin appears well perfused at this point.

Score 2/2 – one for the description of the lesion and one for the note regarding the lack of involvement of the external meatus and tragus.

Outline 4 important steps in the management (4 marks)

Analgesia

Drainage of the haematoma

Assessment for other injury including in the external canal and the medial aspect of the pinna..

Field block of the pinna

Pressure dressing post drainage

Tetanus prophylaxis as appropriate to immunisation status

Close follow up

Score 4/4 - lose 2 points for any of the answers in bold not included.

For this type of injury list 6 indications for referral for formal surgical review and repair (6 marks)

Answer –

- > **Large overlying skin avulsion (approximately 5 mm or greater)**
- > **Severe crush injuries**
- > **Complete or near-complete avulsions or amputations**
- > **Large cartilage defects (approximately 5 mm or greater)**
- > **Obvious devitalization**
- > Large auricular haematomas
- > Wounds that require the removal of more than approximately 5 mm of tissue
- > Significant involvement of the auditory canal

Score out of 6 points. Lose 2 points for any options in bold not included.

What are the contraindications to drainage of this problem in the ED (2 marks)

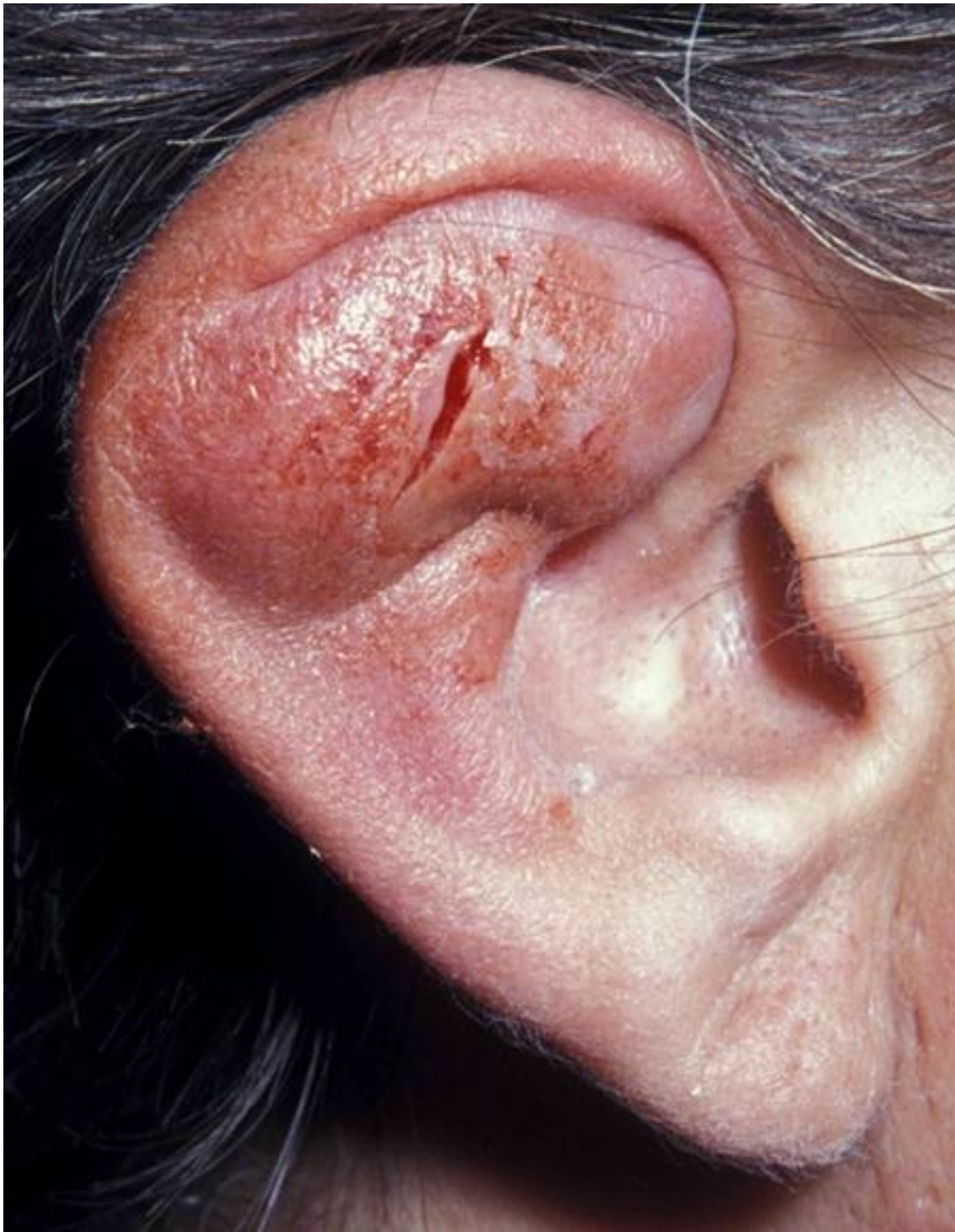Answer –

- Haematomas older than 7 days
- Recurrent or chronic haematomas

(open surgical debridement indicated because the haematoma, granulation tissue, or both can be located within the cartilage instead of in the sub-perichondrial space.)

Score 2/2.

SAQ 8 image



SAQ 9 (9 marks)

A 55 yo male presents after an out of hospital cardiac arrest. He had a 7 minute downtime with effective bystander CPR prior to the arrival of the paramedics. The patient is being hand-bagged via facemask.

Below is the ambulance arrest summary:

Time since ALS start	Rhythm	Action/Drugs
0 minutes	VF	200J shock/CPR IV access
2 minutes	VF	200J shock/CPR 1mg adrenaline 1:10000

The patient arrives at the 3rd minute of the arrest cycle. Fill in the table below for the timing of the next 2 rhythm checks and treatment in that cycle based on the rhythms found. (2 marks)

Time since ALS start	Rhythm	Action/Drugs
<i>4 minutes</i>	<i>VF</i>	<i>200J shock/CPR</i> <i>Amiodarone 300mg bolus</i>
<i>6 minutes</i>	<i>VF</i>	<i>200J shock/CPR</i> <i>1mg adrenaline 1:10000</i>

ROSC is achieved after 8 minutes.

Describe 4 abnormalities in this ECG (2 marks)

Anterolateral ST elevation V1-6

Q waves/poor R wave progression V2-4

Reciprocal changes III/avF

ventricular ectopy

What phenomenon indicates that this patient is at high risk of arrhythmias? (1 mark)

R on T phenomenon of the ventricular ectopic

List 4 management priorities now that the patient has ROSC. (4 marks)

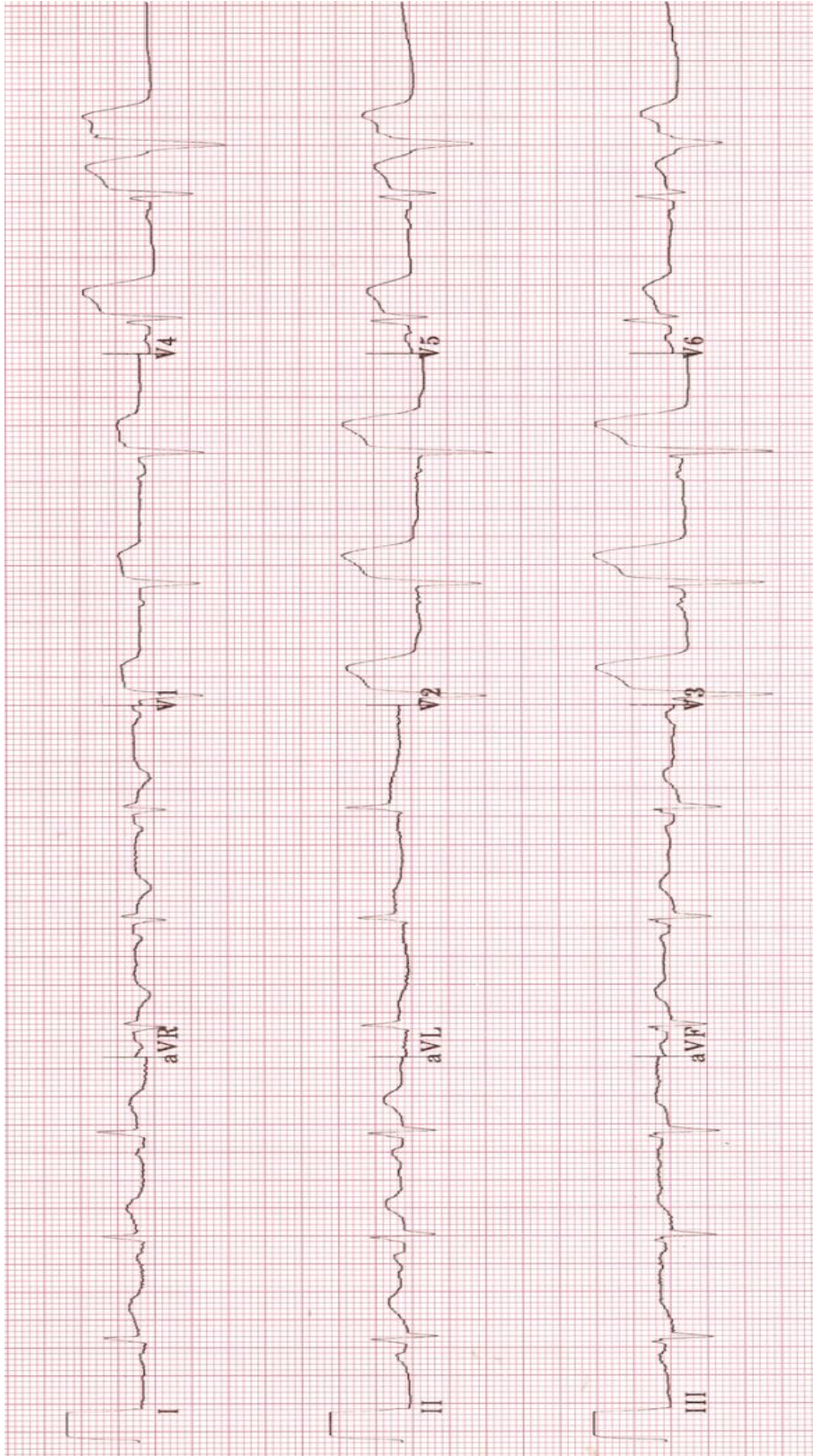
Intubation/airway management

IVF, inotropes if required, sedation

Targeted normothermia

Reperfusion with PCI

SAQ 9 image



SAQ 10 (20 marks)

A 25 year old man has been brought in to your emergency department after sustaining a knife wound to his neck in an assault (see image). His vital signs and GCS are normal.

Describe the injury seen in the picture above: (3marks)

Mention any three of the following:

- Large y-shaped or zigzag left lateral neck wound
- Platysma breached
- Extends through zones III and II
- Blood-soaked gauze
- Soft tissue swelling (suspected expanding haematoma) at the angle of the mandible

Complete the following table for each of the three zones of the neck: (12marks)

1mark for each correct landmark (max 3)

1 mark for angiography (Zone III and Zone I) and 1 mark for operative exploration (max 3)

2marks for correct identification of two anatomical structures in each zone (max 6)

NECK ZONE	ANATOMICAL LANDMARKS	ANATOMICAL STRUCTURES WHICH MAY BE INJURED	INVESTIGATION MODALITY
ZONE III	Angle of mandible to base of skull	Pharynx, jugular veins, vertebral arteries, internal carotid arteries	Angiography Bronchoscopy Oesophagoscopy
ZONE II	Between cricoid cartilage and angle of mandible	Jugular veins, vertebral and common carotid arteries, external and internal carotids, trachea, oesophagus, spinal cord, larynx	Operative exploration

ZONE I	Between clavicles and cricoid cartilage	Lung, trachea, great vessels, oesophagus, spinal cord, thoracic duct, cervical nerve trunks	Angiography Bronchoscopy Oesophagoscopy
--------	---	---	---

List the indications for emergent intubation of this patient: (5marks)

- Stridor
- Acute respiratory distress
- Airway obstruction from blood or secretions
- Expanding neck haematoma
- Profound shock
- Extensive subcutaneous emphysema
- Altered mental state
- Tracheal shift

(Relative indications – no marks for this)

- Progressive neck swelling
- Voice changes
- Progressive symptoms
- Massive subcutaneous emphysema of the neck
- Need to transfer symptomatic patient
- Symptomatic patient with anticipated prolonged time away from ED

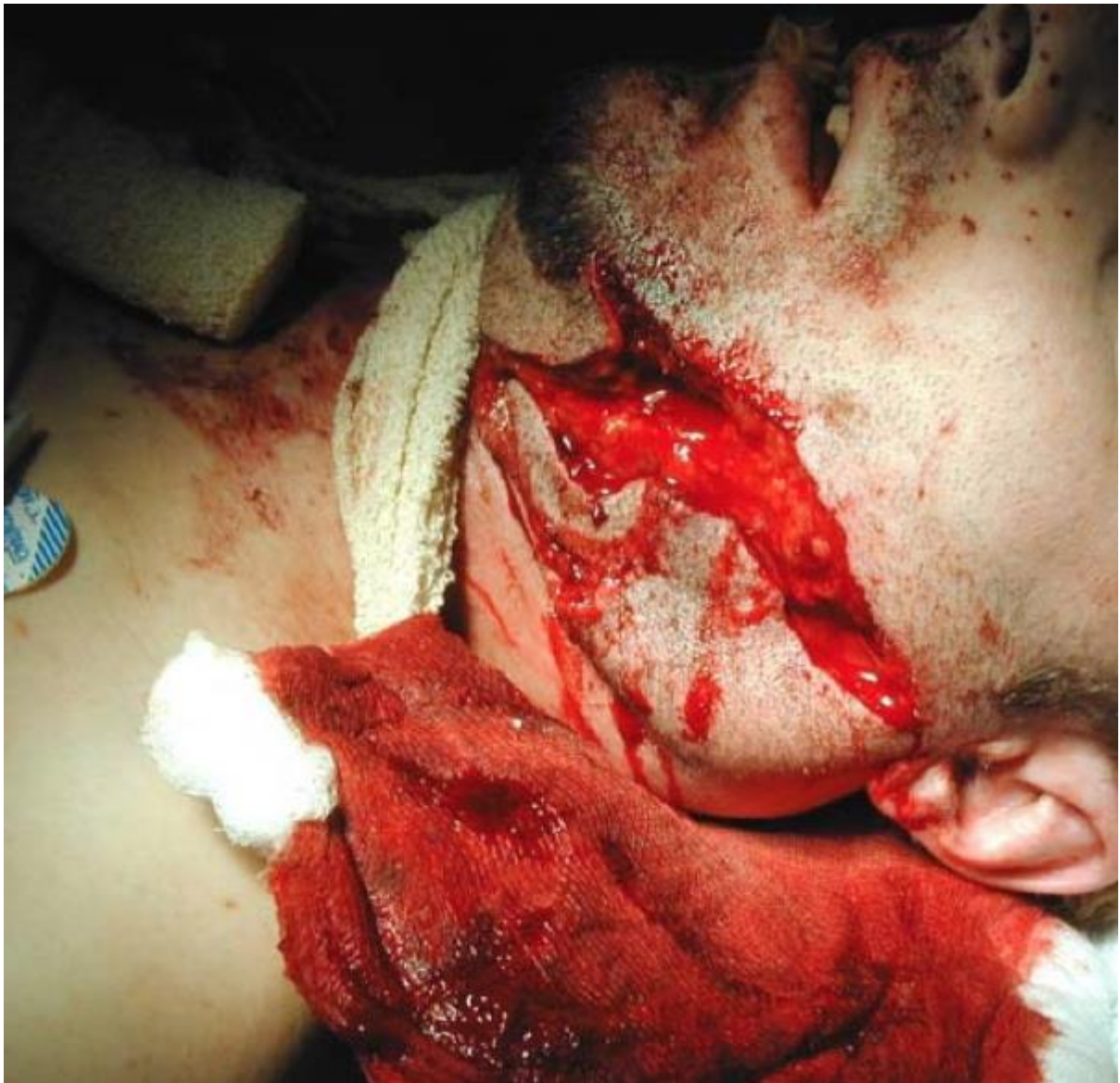TOTAL: ___/20MARKS

Author: Dr Laura Hutchinson (FACEM Wollongong Hospital)

Date created: 11/5/16

Resources: Tintinalli's Emergency Medicine

SAQ 10 image



SAQ 11 (12 marks)

A young woman has presented following a deliberate self poisoning of an unknown amount of venlafaxine. She appeared slightly drowsy on arrival, but was otherwise well. BP 120/70, pulse 80.

She was seen by your junior registrar and had agreed to drink 50g of charcoal and was admitted for observation to a non-monitored bed in your short stay unit.

You are called to review her 6 hrs later due to a change in her status. She now looks unwell, and you are concerned she may have serotonin syndrome.

What are the clinical features of serotonin syndrome ? (3 marks)

- altered mental state + neuromuscular changes + autonomic changes
- altered mental state : agitation, confusion, GCS depression, coma ,seizures
- neuromuscular changes : tremor, myoclonus, hypertonia (esp lower limbs), clonus, ocular clonus
- autonomic changes : hyperthermia, sweating, D&V, hypertension.

What are the pharmacodynamics effects of venlafaxine? (1 mark)

SSRI + noradrenaline reuptake inhibitor

List two errors made by your registrar in the management of this patient. Why were these errors? (2 marks)

- high risk delayed seizures, risk of aspiration as given charcoal
- admitted to general ward, unknown amount of venlafaxine taken , well described dose-dependant seizure risk, and CVS instability with very high doses (>8gm).

How would you manage her suspected serotonin toxicity? (4 marks)

- monitored bed/ HDU
- benzodiazepines – titrated IV boluses midazolam/diazepam
- cyproheptadine – note : can increase risk of seizures, therefore give benzodiazepines first, and if not improving give cyproheptadine

(5) List 3 classes of drugs that can cause serotonin toxicity, with 2 examples from each class. (4 marks)

SSRI : fluoxetine, fluvoxamine, paroxetine, citalopram, sertraline, escitalopram

MAO inhibitors : phenelzine, moclobemide

Serotonin releasing agents : amphetamines, MDMA, ecstasy

Misc : lithium, tryptophan

SAQ 12 (12 marks)

A four day neonate presents to the Emergency department. The child is shocked. Observations are RR60, HR 190, Capillary refill time centrally is 5 secs. They are responsive to pain.

List three antenatal / perinatal risk factors for neonatal sepsis (3 marks)

Maternal colonisation with group B streptococcus (positive high vaginal swabs for GBS), prematurity, maternal peri-partum illness / fever / infection, prolonged rupture of membranes (greater than 24hrs prior to delivery)

Give three differential diagnoses of neonatal collapse other than sepsis (3 marks)

Inborn error of metabolism, **congenital cardiac disease**, non-accidental injury

What empiric therapy would you commence (be specific) (3 marks)

Move to resuscitation area, cardiac and saturation monitoring, high flow oxygen, IV access, **fluid bolus 20mls/kg of Normal saline**, IV antibiotics (must state which one/s) , IV antivirals ((must state which one) , dextrose if low BSL

List 6 investigations you would order (3 marks)

Bloods (FBC, UEC, Blood culture

FBC

UEC

Blood cultures

Bedside glucose, chest xray

VBG

LP - delayed

SAQ 13 (12 marks)

A 33 yo man presents following a single punch knocking him to the ground. He had a GCS of 7 on arrival and has been intubated prior to CT scan.

He has returned to the ED following CT of his brain and cervical spine.

CT of the cervical spine is normal and he has no other injuries.

His current observations are pulse 60/min and BP 155/85 mmHg. His pupils are equal and reactive.

A single image from his brain CT is attached

Describe 3 abnormalities on the CT image (2 marks)

- 1.1.acute right subdural haematoma.....
- 1.2.midline shift to the left.....
- 1.3effacement of R lateral ventricle.....

The neurosurgical team is en route to hospital and the patient will be going to the operating theatre in approximately 1 hour.

Assuming his clinical status remain unchanged, describe 8 treatments and their therapeutic target which should be performed in the ED prior to transferring this patient to theatre (8 marks)

	Treatment	Therapeutic target
1	Maintain low end normocarbia	Adjust TV and RR to achieve pCO2 35-45
2	Position 30 degrees head up	Prevent further raised ICP from venous pressure
3	Ensure ETT ties and cervical collar not tight	ditto
4	Maintain normoglycaemia – dextrose or insulin as needed	Keep by BSL between 6-10mmol/L
5	Maintain normothermia	Keep core temperature between 35-37 degrees with Bair Hugger, warm fluids or antipyretics
6	Maintain optimal BP with fluids (N saline 500ml boluses) or vasopressors as indicated.	Keep MAP between 70-85mmHg

	Avoid hypertension (see below)	
7	Ensure adequate sedation and paralysis eg propofol 5-10mg/hr and vecuronium 10mg	Avoid/treat hypertension, agitated, coughing, gagging due to under sedation/paralysis, all of which will further increase ICP
8	Decompress bladder with IDC	Avoid hypertension due to bladder distension
9	Decompress stomach	Minimise risk of aspiration, optimise ventilation
10	Maintain adequate oxygenation	Adjust FiO2 to achieve sats >95% and avoid hyperoxia (<99%)
11	Treat anaemia	Keep Hb >10g/dl to ensure adequate O2 delivery, transfuse blood as needed
12	Treat seizures - midaz 5mg if seizing, then phenytoin 20mg/kg	Avoid further brain injury from seizure activity - no evidence to support prophylactic anti-epileptics

Must name at least 2 methods to avoid raised ICP (CO2, ETT ties, collar), must name BP control, any 5 others

30 minutes later his left pupil becomes fixed and dilated, his pulse rate is 50/min and his BP 160/100 (2 marks)

Describe two additional treatments, with dosage where relevant, that you would immediately institute

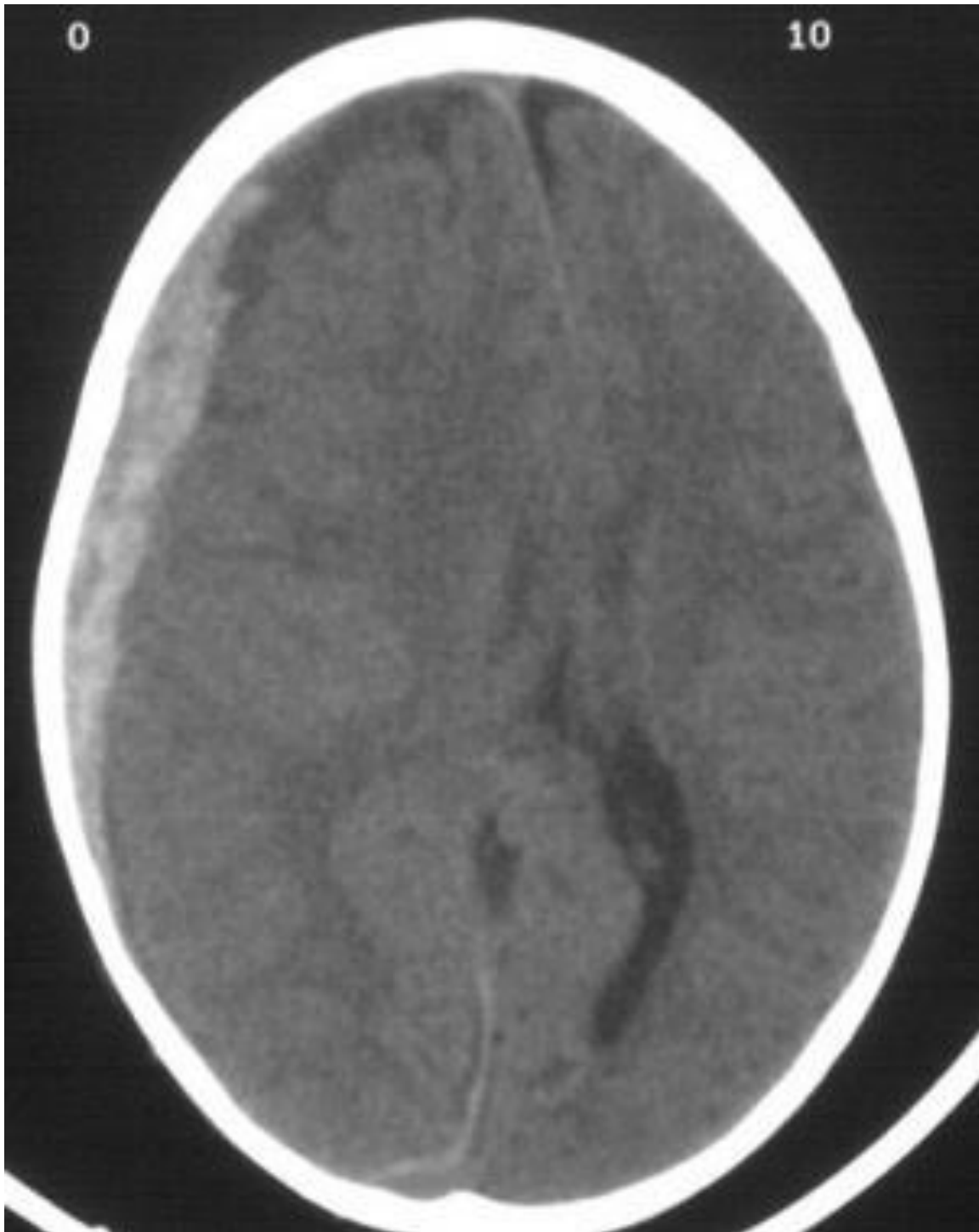
3.1 Hyperventilate to pCO2 30-35

3. 2 Give mannitol 20% 0.5-1g/kg

3.3 Give hypertonic saline e.g. 250ml of 3% saline

Either 3.1 (1 mark) and 3.2 or 3.3 (1 mark) –including strength and dose/kg

SAQ 13 image



SAQ 14 (9 marks)

A 30 yr old Nepalese man presents with fever and confusion. He is noted to have dullness to percussion on his right lung base. His CxR is attached.

You do a pleural tap. List five investigations you would order on the pleural fluid and justify your responses (4 marks)

Pleural fluid : protein, LDH, glucose (<3.3 mmol/L associated with empyema, rheumatoid, SLE TB, malignancy), pH (<7.2 indicates pleural infection and indication for drainage if parapneumonic).

Wcc and differentials

Cytology

HCT if suspect haemothorax (if bloody HCT <1% not significant, 1-20% malignancy/PE/trauma, >50% haemothorax).

Gram stain and culture, + AFB

Serum protein and LDH for comparison

List 2 biochemical features that differentiate a transudate from an exudate (2 marks)

Light's criteria :

Exudate if one or more of the following criteria are met (sens 98%, spec 83%)

pleural fluid protein : serum protein >0.5

pleural fluid LDH: serum LDH >0.6

pleural fluid LDH > 2/3 upper limit of normal serum LDH

additional criteria if results equivocal:

serum albumin – pleural albumin < 1.2 g/dL

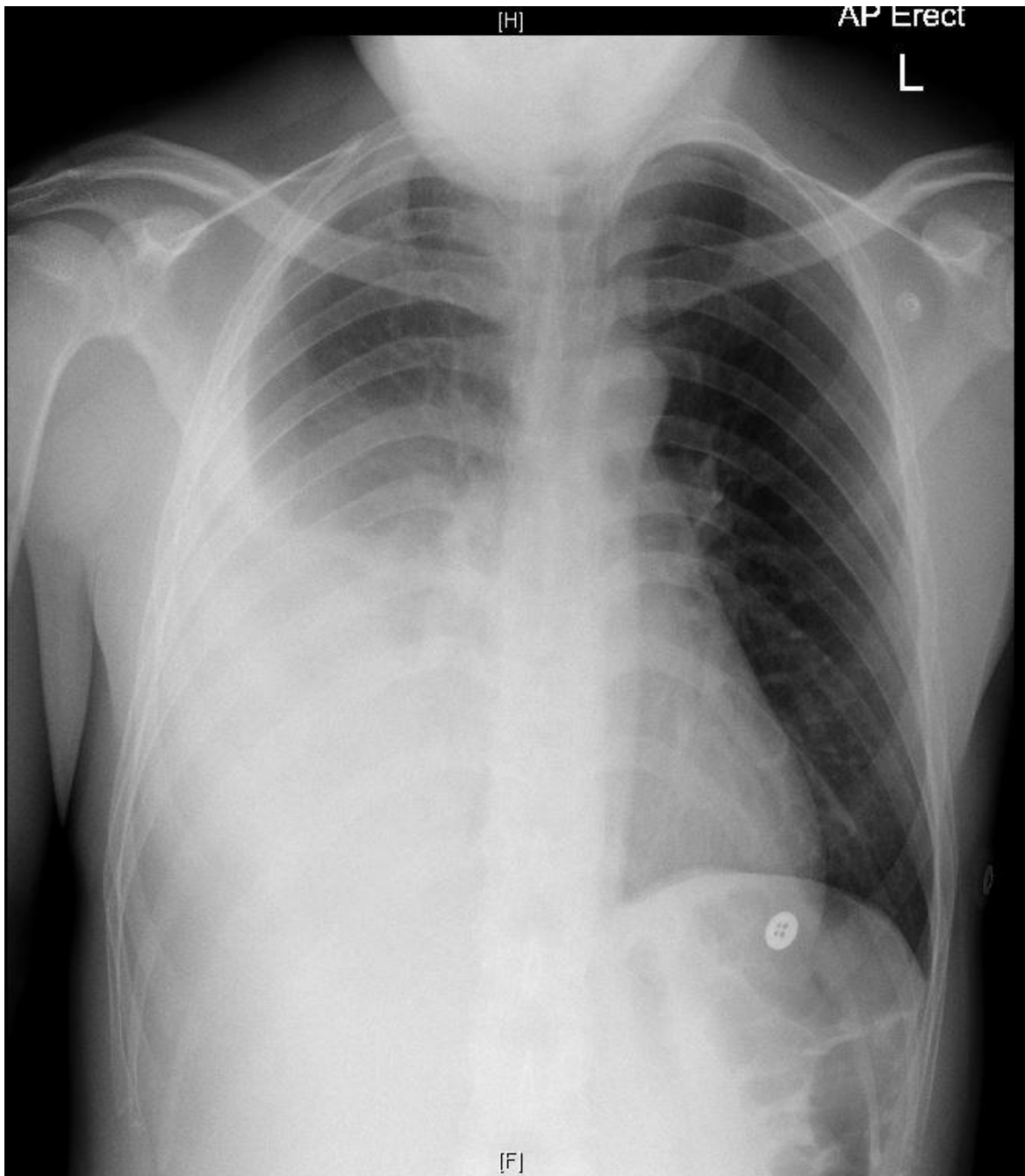
Name 3 common causes of transudates and 3 common causes of exudates that cause pleural effusions (3 marks)

Transudates : Common causes: CCF, cirrhosis, hypoalbuminaemia, (other : hypothyroidism, nephrotic syndrome)

Exudates : common : pneumonia (bacterial, fungal, TB) ; malignancy ; pulmonary infarction from PE.

(others : oesophageal rupture, pancreatitis, intra abdominal abscess, collagen vascular diseases, post CABG, asbestos, sarcoidosis)

SAQ 14 image



SAQ 15 (10 marks)

A 10 year old boy presents to the Emergency department with abdominal pain.

What clinical features of the history and examination make a diagnosis of appendicitis more likely? (4 marks)

Right iliac fossa pain, Pain migrating to right iliac fossa, duration less than 3 days, anorexia, vomiting, fever, right iliac fossa tenderness, pain on hopping, pain on coughing, pain on movement or walking

After history and physical examination, you decide the most likely diagnosis is appendicitis but want to exclude other causes of abdominal pain in children. List four tests and the diagnosis they would exclude in the table below (4 marks)

<u>Test</u>	<u>Diagnosis</u>
serum glucose	Diabetes Mellitus / diabetic ketoacidosis
urine analysis (dipstick)	urinary tract infection
liapse / amylase	pancreatitis
Chest xray	Perforation / LRTI
ultrasound	intussusception

After referral to the Surgical registrar on call you are asked to keep the child nil by mouth. Please prescribe maintenance fluid in the table below for the next 12 hours. Assume only 1000ml bags of intravenous fluid are available (2 marks)

Date	Route	Type of fluid	Additive and dose	Total volume	Rate (ml/hr)
	IV	Normal Saline + 5% Dextrose (Glucose) 0.9% Saline + 5% Dextrose (Glucose) 0.45% Saline + 5% Dextrose (Glucose)	20-40mmol Potassium chloride	1000	78 - 82 mls/hr

SAQ 16 (13 marks)

A 25 year old gym owner presents to ED with a left lower leg injury after being tackled at football training. Impact was lateral with the opponent landing on him. He has intense pain and swelling of the lower leg. There is no disruption of skin. The initial X rays are provided.

List the abnormalities evident on the images (5 marks)

Answers

a) Abnormalities

- **Minimally displaced Weber C spiral fracture of the proximal fibula (Maisonneuve fracture).**
- **Lateral and posterior subluxation of the talus > 5mm.**
- Disruption of the tibiofibular syndesmosis
- **Posterior malleolar fracture of the tibia with >5mm displacement of the fragment.**
- Associated soft tissue oedema

Score 5/5. Must have all answers in bold or maximum score 2/5.

What are the potential acute complications with this injury? (2 marks)

- Compartment syndrome
- Common/deep peroneal nerve injury

Score 2/2

List 3 methods of providing analgesia in this case. (3 marks)

- Pharmacological –
 - a. Inhalational - Nitrous oxide/methoxyflurane
 - b. Parenteral – opiates/ NSAIDs/ketamine
 - c. Enteral – paracetamol/ NSAIDs/opiates
- **Physical – reduction and splinting**

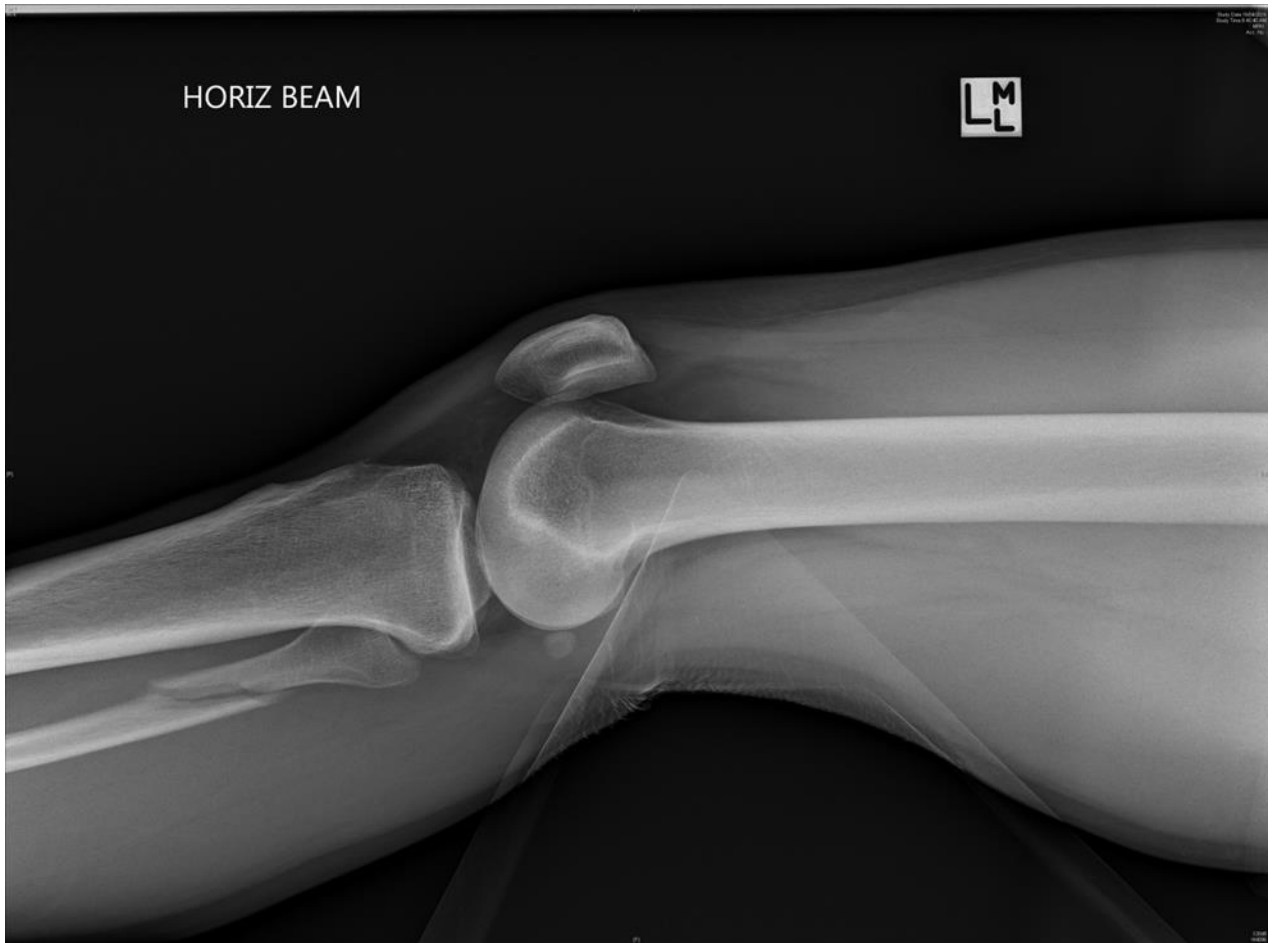Score 3/3. Must include answer in bold or maximum score 1/3

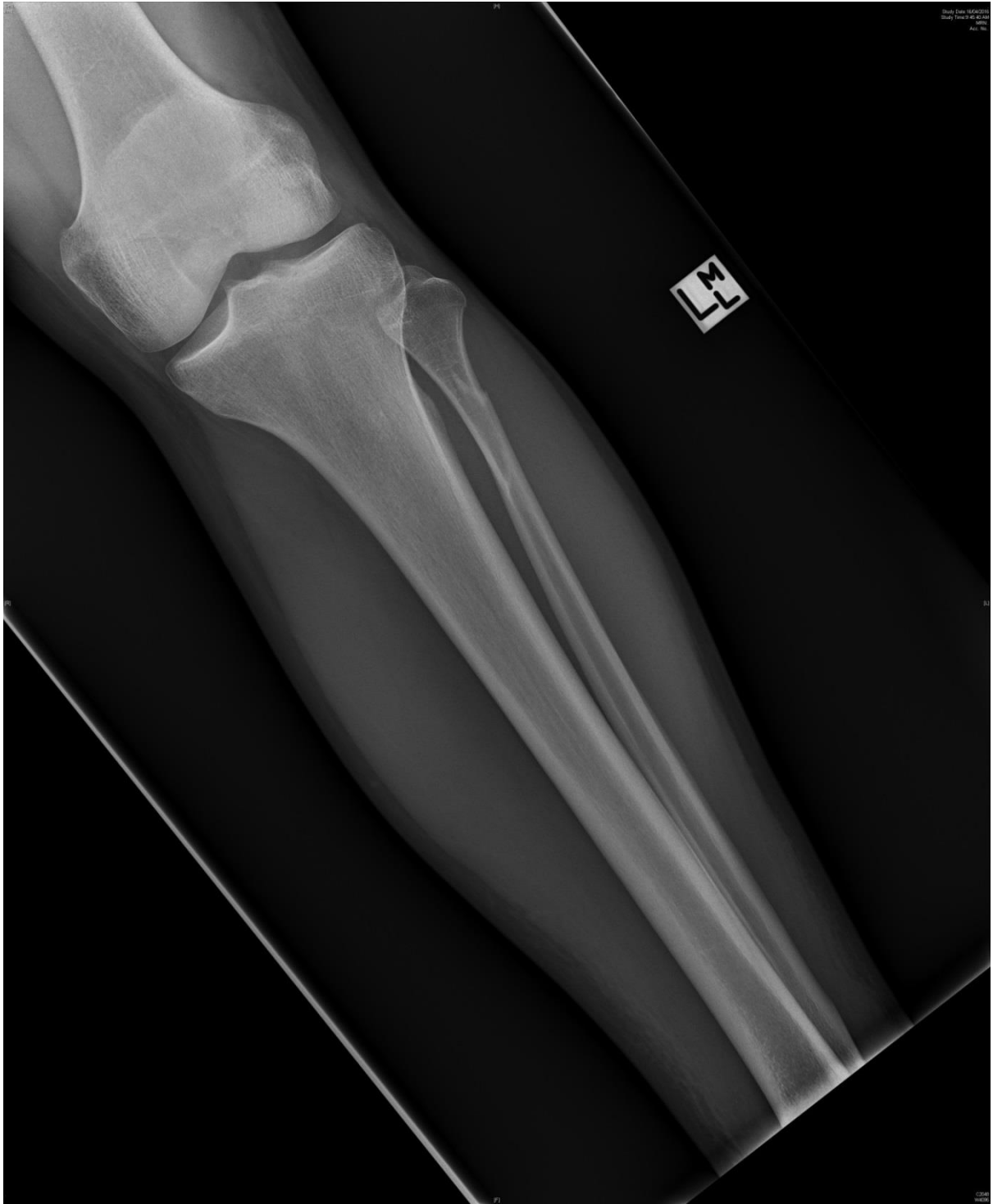List 3 methods of assessing for tissue compartment syndrome (3 marks)

- **Clinical – Pain, Paraesthesia, Paralysis, Pallor, Poikilothermia (+/- pulselessness)**
- Pressure manometers – commercial
- Lab tests – CPK

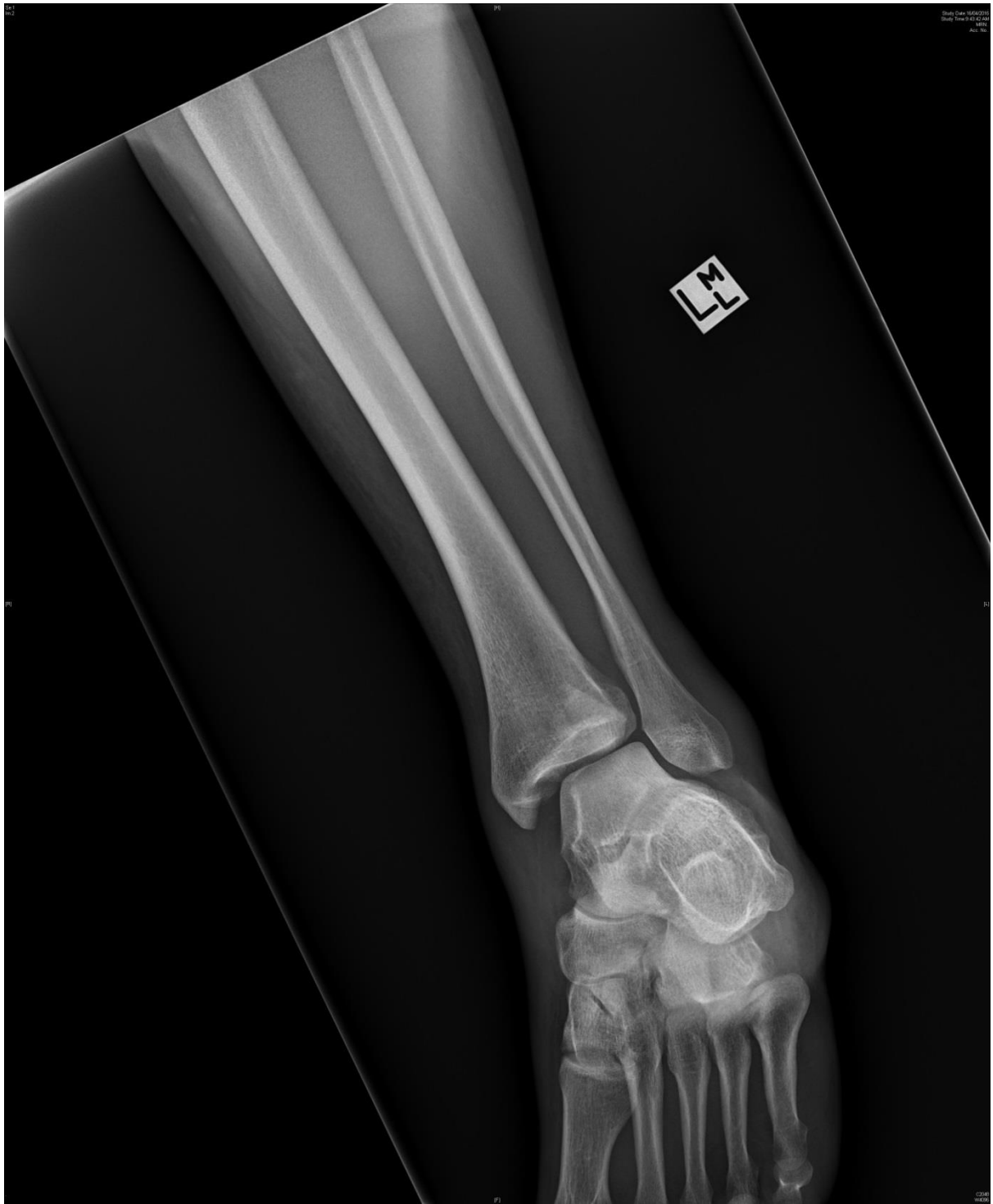Score 3/3. Must include Clinical with at least the 5 Ps or maximum score is 1/3.

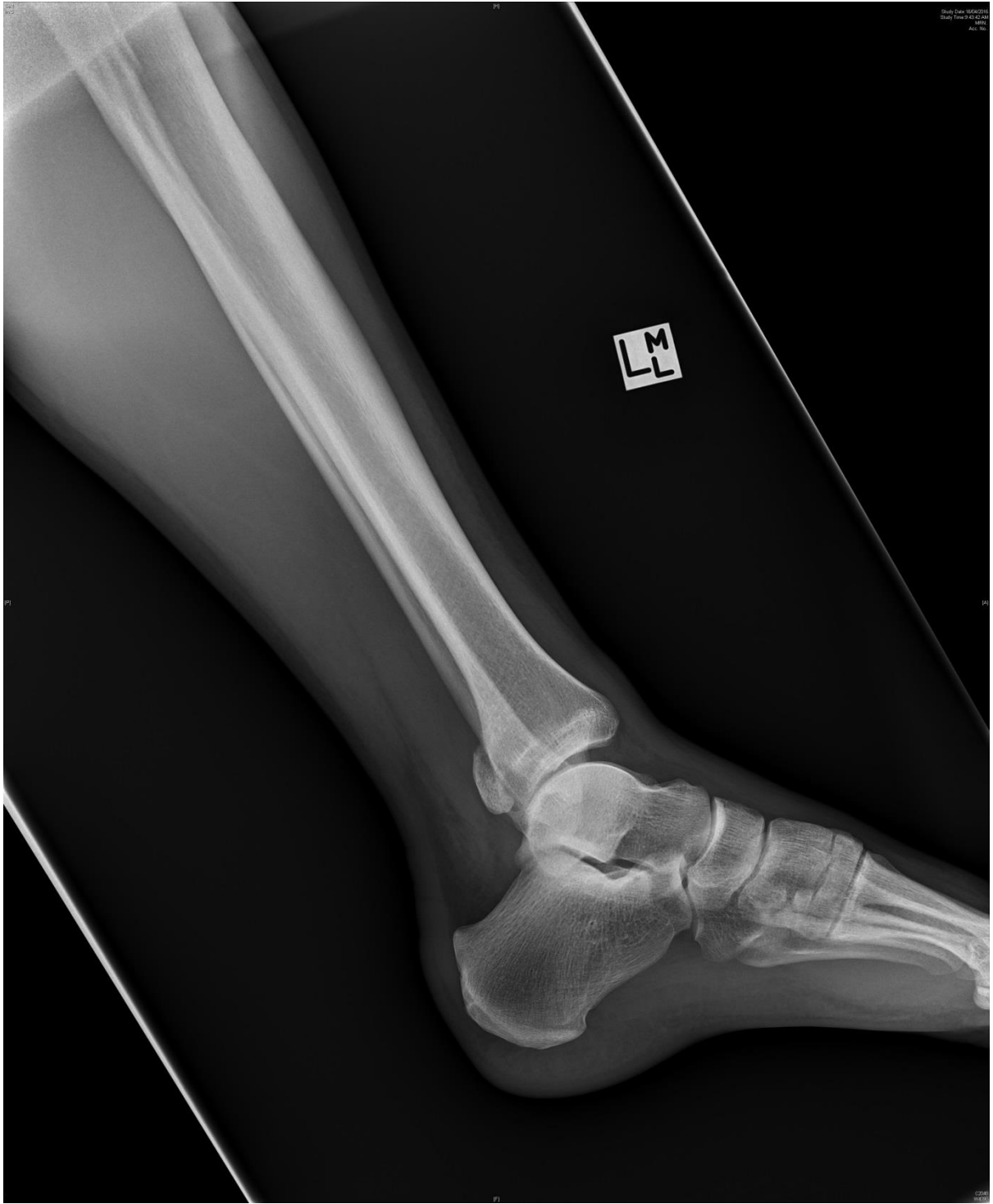SAQ 16 images

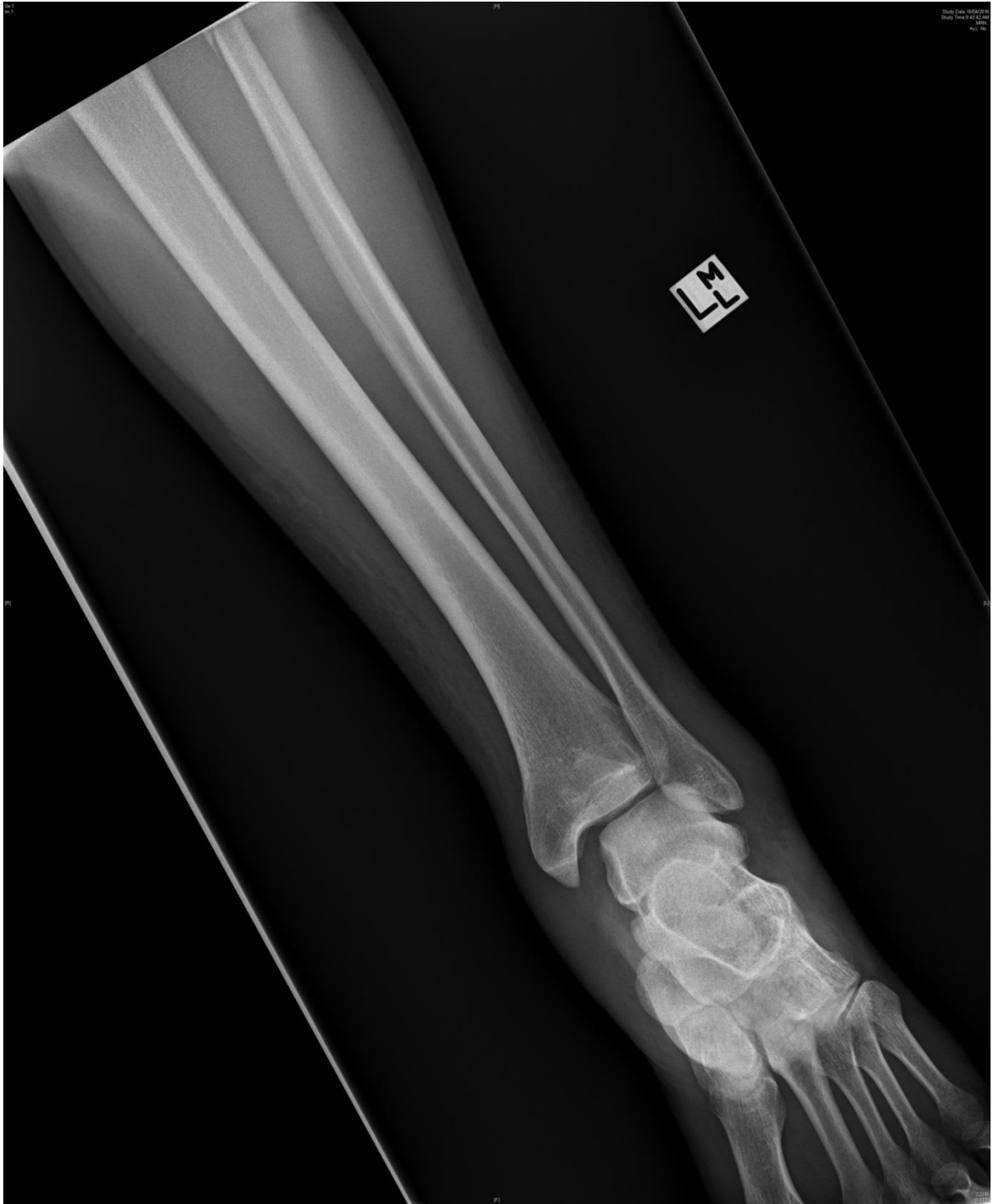











SAQ 17 (12 marks)

A 4 year old boy is brought in to the Emergency Department by his concerned parents. He has been unwell with a fever for 6 days. He has a diffusely erythematous pharynx and a unilateral 3cm cervical lymph node on the right. See attached images.

What is the most likely diagnosis (1 mark)

1. Kawasaki disease

Give 4 differential diagnosis (2 marks)

- a. Viral exanthems
- b. Strep disease: eg scarlet fever, toxic shock syndrome
- c. Staph disease: eg scalded skin syndrome, TSS
- d. Steven Johnsons syndrome
- e. Drug reaction

Outline the typical features of this condition? (4 marks)

2. Clinical criteria to diagnose 'typical' KD:
 - A. fever for 5 or more days, and
 - B. at least 4 out of 5 of:
 - a. bilateral non-exudative conjunctivits
 - b. oropharyngeal mucous membrane changes: pharyngeal erythma, red/cracked lips, 'strawberry' tongue
 - c. cervical lymphadenopathy
 - d. peripheral extremity changes: acute: diffuse erythema and swelling of hands/feet, convalescent phase: desquamation
 - e. polymorphous generalized rash

List 2 potential complications? (2 marks)

The primary complications of Kawasaki disease (KD) are cardiac sequelae, although noncardiac complications also may occur ([table 1](#)). (See '[Introduction](#)' above.)

•KD shock syndrome (KDSS), defined as sustained systolic hypotension or clinical signs of poor perfusion, is a potentially life-threatening complication. (See '[Shock](#)' above.)

•Macrophage activation syndrome (MAS) is a rare and potentially life-threatening complication of KD that should be considered in patients with persistent fever after intravenous [immune](#)

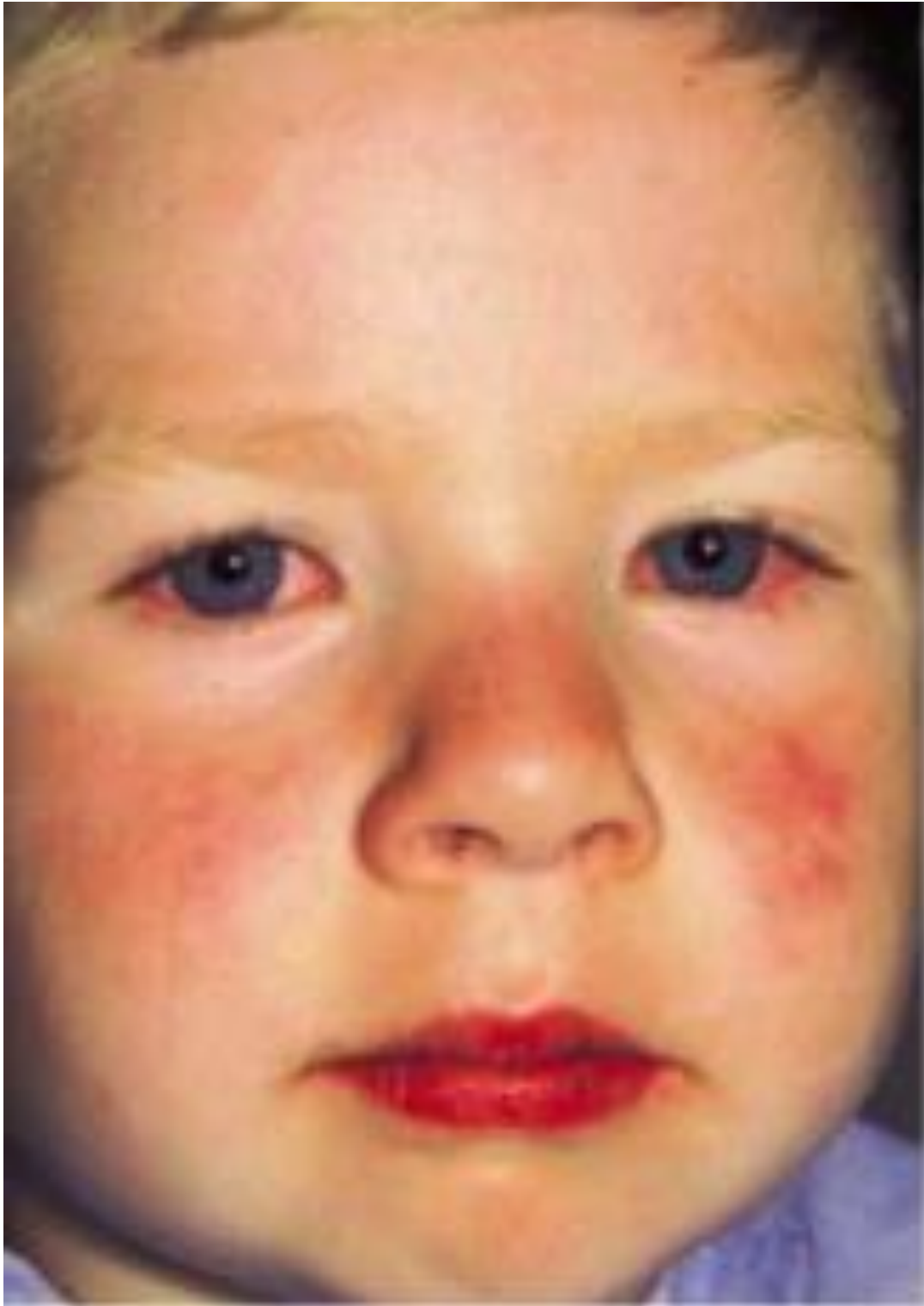globulin (IVIG) therapy. (See 'Macrophage activation syndrome' above and "Clinical features and diagnosis of hemophagocytic lymphohistiocytosis", section on 'Rheumatologic disorders/MAS'.)

- The major complication of KD is coronary artery (CA) aneurysms. However, other cardiac sequelae can occur, including decreased myocardial contractility, coronary arteritis without aneurysms, mild valvular regurgitation (primarily mitral valve involvement), and pericardial effusion. Acute myocardial infarction is the main cause of death in KD. (See 'Cardiac complications' above and "Cardiovascular sequelae of Kawasaki disease".)
- Vascular changes also may occur in peripheral arteries. Peripheral arterial obstruction can lead to ischemia and gangrene. (See 'Noncoronary vascular involvement' above.)
- Urinary abnormalities and renal disease, with the exception of sterile pyuria, are uncommonly associated with KD. (See 'Urinary abnormalities and renal disease' above.)
- Children with KD may present with a wide variety of gastrointestinal manifestations, rarely including acute abdominal catastrophes. (See 'Gastrointestinal abnormalities' above.)
- Sensorineural hearing loss, usually transient and asymptomatic, can be seen following KD. (See 'Central nervous system' above.)

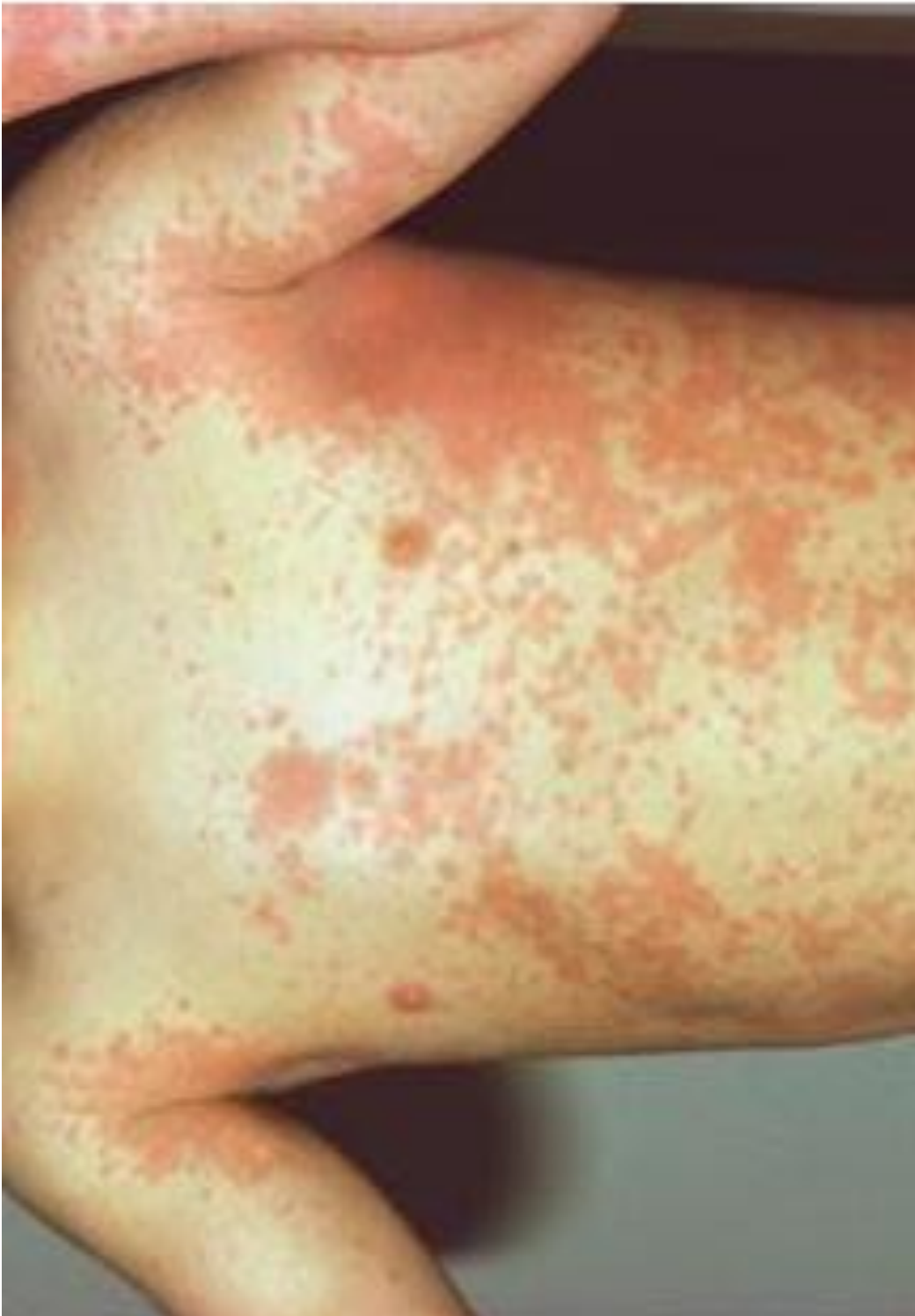Outline your management? (4 marks)

1. Specific management: **IV immunoglobulin** with high dose **aspirin**, echo.
Supportive; Fluids/analgesia/etc if indicated.
Disposition: Admit

SAQ 17 images



SAQ 17 images



SAQ 18 (10 marks)

A 74yo woman presents with lightheadedness, lethargy and palpitations.

Her vital signs are BP 100/60, HR 124/min, temp 37, SaO₂ 99% on room air.

She has a past medical history of type 2 diabetes, hypertension and has a pacemaker for heart block. Her pacemaker card indicates she has a DDD pacemaker.

Describe the DDD function of her pacemaker (2 marks)

- a. Dual (atrial and ventricular) chamber pacing. (0.5)
- b. Dual (atrial and ventricular) chamber sensing. (0.5)
- c. Dual response to sensing in that it will trigger or inhibit pacing depending on the underlying rhythm. (1)

Her ECG is enclosed.

Describe her ECG (2 marks)

- i. Broad complex tachycardia (HR 120/min) with a ventricular pacing spike before every complex. (1)
- ii. Absence of p wave before each ventricular pacing spike indicating that the pacemaker is not triggered by a native atrial rhythm. (1)
- iii. Absence of atrial spike before each ventricular pacing spike indicating that there is no atrial pacing. (1)

List 2 differential diagnoses (2 marks)

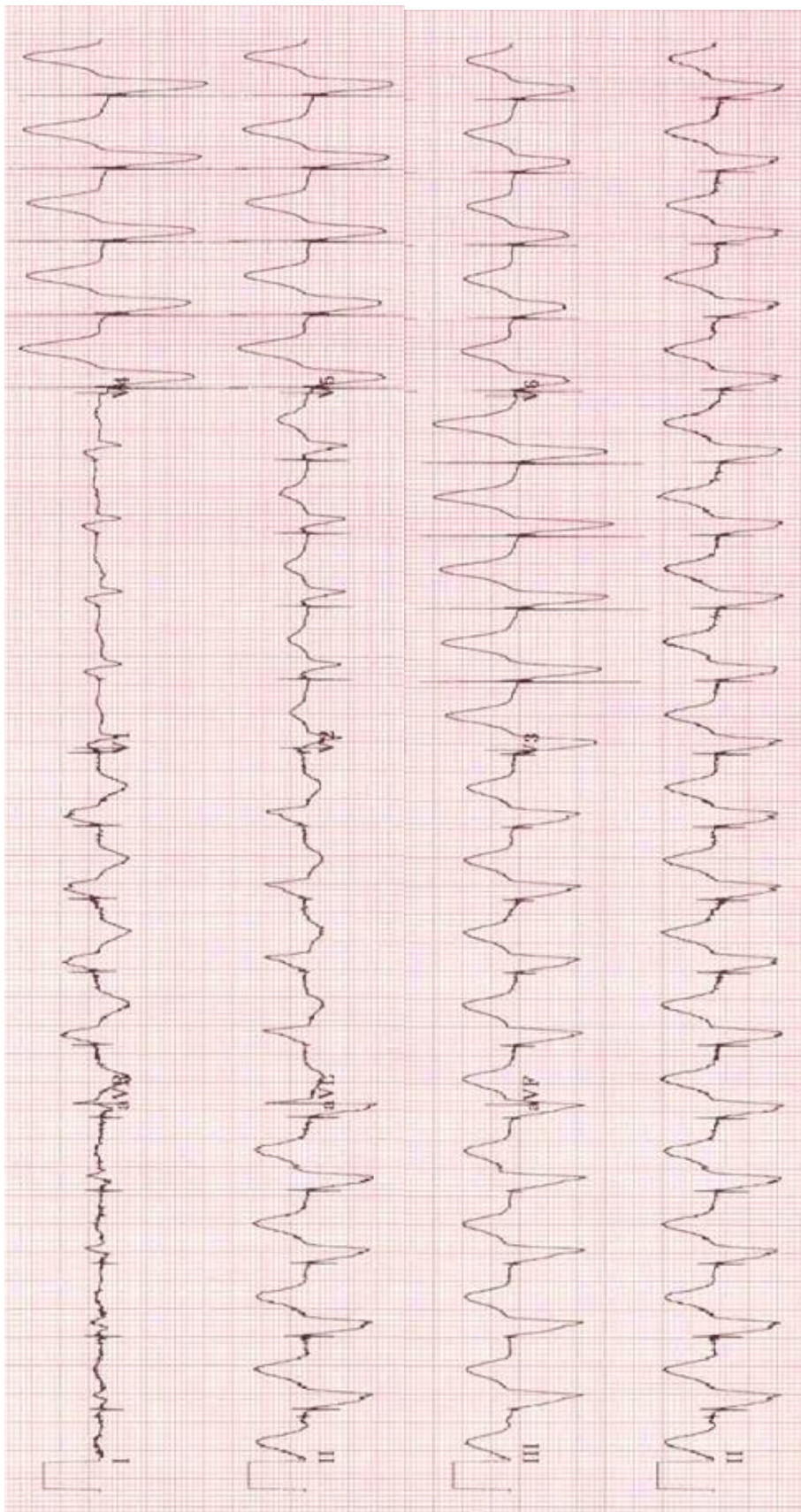
- i. Pacemaker mediated tachycardia (PMT). A re-entry tachycardia is created by the pacemaker forming an anterograde pathway and the AV node acting as a retrograde pathway. The retrograde p wave is sensed as native atrial activity and further ventricular pacing is propagated causing the inappropriate tachycardia. (1)
- ii. Sensor-induced tachycardia. The sensor may misfire from 'noise' such as vibrations, loud noises, hyperventilation, surgical electrocautery, etc. (1)
- iii. Lead displacement dysrhythmia. A dislodged pacemaker lead may be irritating the myocardium. (1)

List 4 management steps you would initiate for her (4 marks)

- a. Urgent cardiology referral and pacemaker interrogation. (1)

- b. Apply a magnet over the pacemaker which will inhibit sensing and activate asynchronous ventricular pacing at the preset demand rate. This will block the anterograde circuit and can terminate PMT. (1*)
- c. Vagal manoeuvre (carotid sinus, vasalva) can block AV conduction to terminate PMT. (1)
- d. Adenosine or verapamil can block AV conduction to terminate PMT. (1)
- e. CXR looking for fractured or displaced pacemaker leads. (1)
- f. EUCs looking for hyper/hypokalaemia, hypomagnesaemia. (1)

SAQ 18 image



SAQ 19 (10 marks)

A four year old girl presents to the Emergency department with an isolated Left elbow injury after falling 2 metres from a climbing frame in a local park. She is in severe pain and refusing to move her arm.

Describe how you would manage her pain giving doses and routes of drugs (4 marks)

Intranasal fentanyl 1-2microgrammes / kg,

Intravenous Morphine 0.05-0.1mg / kg

Oral or Rectal Paracetamol 15-30mg / kg

Oral Ibuprofen 5 – 10mg / kg

Oral Oxycodone 0.1mg/kg

Inhaled nitrous oxide

Splint arm / sling arm / apply above elbow backslab / protect elbow

Distraction / play therapy / keep parent with child

Her x-ray is attached, describe four abnormalities shown (4 marks)

Abnormal / pathological anterior fat pad

Posterior fat pad

Transverse fracture of distal humerus

Dorsal angulation of distal fragment

Abnormal anterior humeral line

List two immediate / early complications of her injury (2 marks)

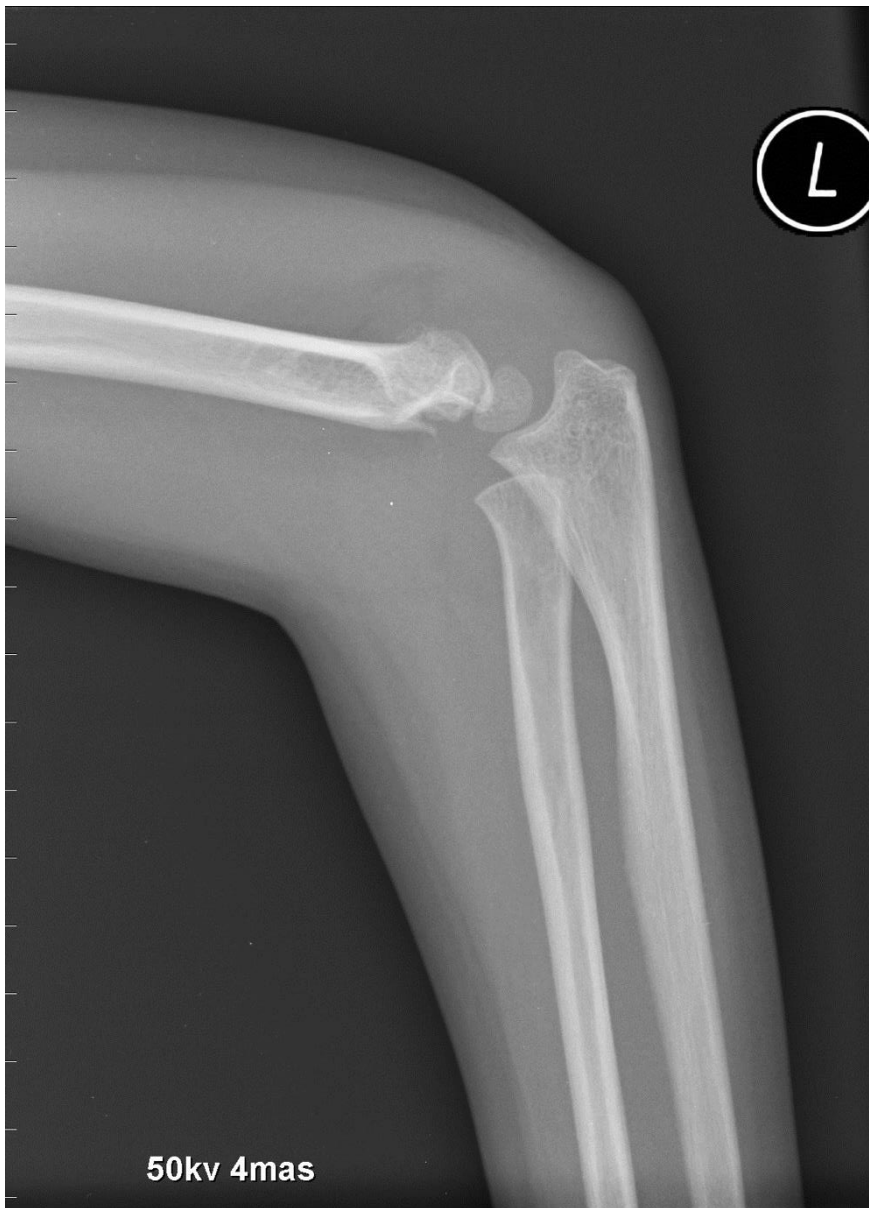Brachial artery injury / dissection,

Compound or open injury

Peripheral nerve injury

Tendon injury

SAQ 19 image



SAQ 20 (9 marks)

A 24 year old man with a history of hydrocephalus presents with headache, malaise and fever. He has a ventriculoperitoneal shunt.

Aside from the peritoneal cavity, list 2 other potential sites for the drainage limb of a ventricular shunt (2 marks)

1. Pleural cavity, right atrium, ureter, gall bladder (2 marks)

Apart from infection, list 3 causes of shunt obstruction (3 marks)

1. Prox: tissue debris, choroid plexus, clot, infection, catheter tip migration, localized immune response to tubing
Distal: Kinking/disconnection of tube, pseudocyst formation, infection

What is the most commonly cultured micro-organism in CSF shunt infections? (1 mark)

Staph epidermidis

What is the role of lumbar puncture in a patient with a ventriculoperitoneal shunt? (1 mark)

No role, May be negative in presence of shunt infection.

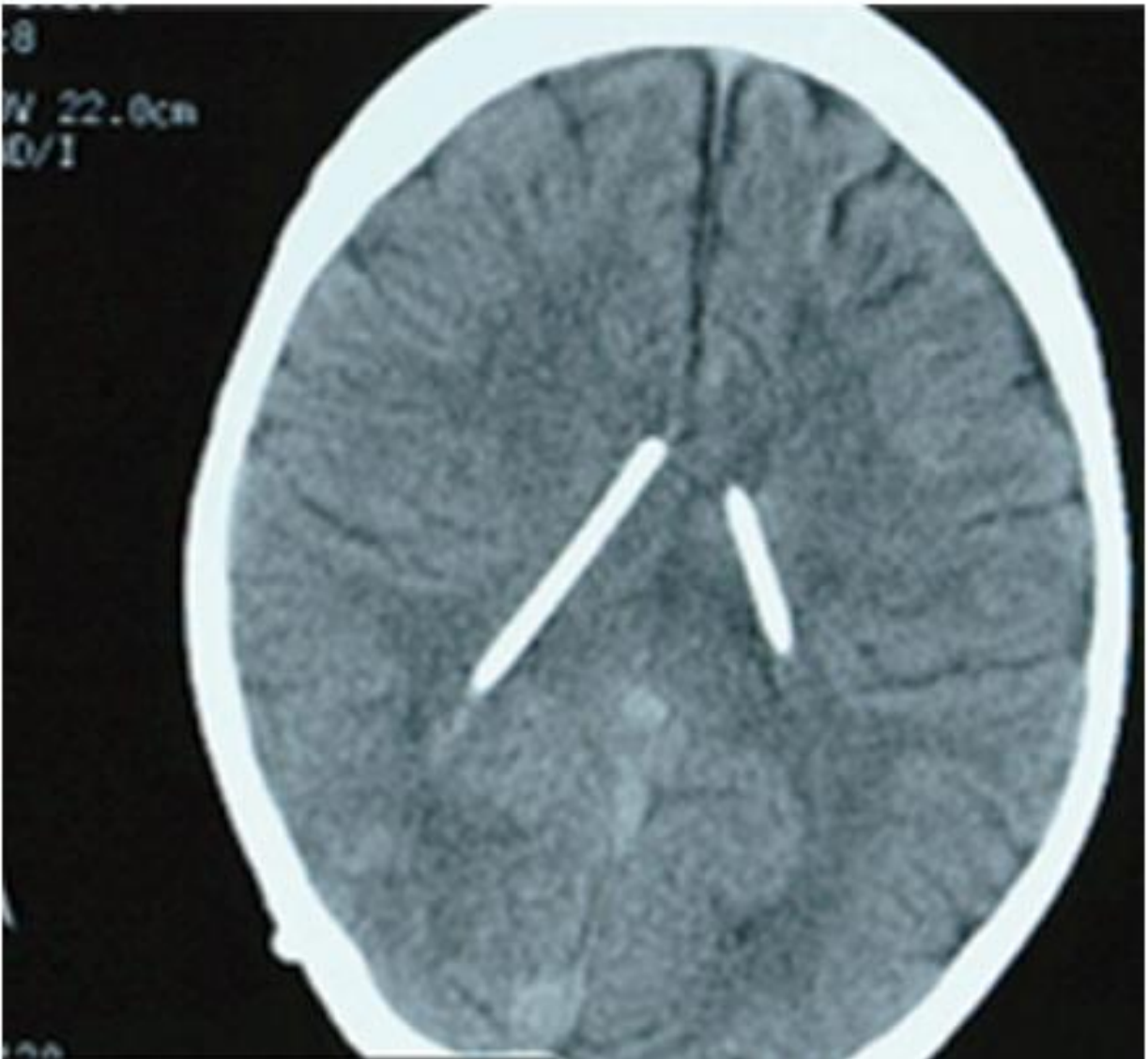
His CT image is attached. What is the diagnosis (2 marks)

1. Slit ventricle syndrome (2 marks). often presents with waxing and waning symptoms. The CT is often helpful in distinguishing it from other causes of malfunction. Overdrainage and the slit ventricle syndrome are seen in approximately 5% of patients with shunts. Because of overdrainage, the tissues actually occlude the orifices of the proximal shunt apparatus. As intracranial pressure increases, the same occluding tissue is disengaged, which allows drainage to resume. This phenomenon is cyclical and is responsible for the episodic or waxing and waning aspect of the presenting complaint. Patients present with episodes of elevated intracranial pressure caused by a transient obstruction of the ventricular catheter from a collapsed ventricle. Decreased cerebral compliance may prevent the ventricles from fully expanding as intracranial pressure and volume increase, which further contributes to ventricular collapse. The rate of this complication is lower for currently used shunt systems with antisiphon devices and programmable shunt valves

Author: M Taliana, Maitland Hospital

Source: Ch 169 Tintinalli

SAQ 20 image



SAQ 21 (10 marks)

A 62 year old male with a history of chronic pancreatitis presents to the Emergency Department with several days of nausea and vomiting. His biochemistry profile is attached.

Interpret the abnormalities in the results(3 marks)

- a) Severe metabolic alkalosis with respiratory compensation

High anion gap (approx. 31) metabolic acidosis

Profound hypochloraemia

Gastric losses and fluid depletion causing chloride loss and metabolic alkalosis

Metabolic acidosis secondary to renal failure (acute? Acute on chronic?) +/- sepsis from pancreatitis and/or gastro-enteritis

CO₂ retention as compensation for severe metabolic alkalosis

Give likely underlying causes for the main metabolic acid-base disturbances (3 marks)

- a) Causes of a hypochloraemic metabolic alkalosis:

Recurrent vomiting

Gastric acid loss,

Diuretic-induced alkalosis (loop or thiazide diuretics)

Posthypercapnic metabolic alkalosis.

CLD, cystic fibrosis, and laxative abuse are also potential causes.

Describe the clinical features of severe hypocalcaemia (2 marks)

- a) Carpopedal spasm, tetany, seizures, decreased cardiac function, or prolonged QT interval

Outline your management of symptomatic hypocalcaemia (2 marks)

- a) Intravenous calcium replacement with either 10% calcium gluconate or 10% calcium chloride, followed by a calcium infusion.

Hypomagnesaemia should also be treated, with IV magnesium supplementation

SAQ 21 image

Parameter	Patient Value	Normal Adult Range
Arterial Blood Gas		
FiO ₂	0.4	
pH	7.62*	7.35 – 7.45
PCO ₂	62 mmHg* (8.2 kPa)*	36 – 45 (4.6 – 6.0)
PO ₂	133 mmHg (17.5 kPa)	
Bicarbonate	65 mmol/L*	21 – 28
Base Excess	> 30 mmol/L*	-3 – +3
Sodium	149 mmol/L*	135 – 145
Potassium	3.3 mmol/L*	3.5 – 5.2
Chloride	53 mmol/L*	95 – 110
Calcium ionised	0.74 mmol/L*	1.12 – 1.32
Lactate	2.7 mmol/L*	< 1.3
Venous biochemistry		
Urea	34.9 mmol/L*	3.0 – 8.0
Creatinine	431 micromol/L*	60 – 110

SAQ 22 (12 marks)

You are preparing a presentation on the management of patients who present to the emergency department in labor, and the delivery is imminent. Fill in the following table describing signs and management of common problems in labor.

Problem	Signs	management
Nuchal Cord	Cord around baby's head	If loose, can pull over baby's head. If tight then place 2 clamps and cut between them.
Shoulder Dystocia	"turtle sign", head comes out but then goes back in Anterior shoulder impacted below pubic bone	Get help Drain Bladder Consider episiotomy Mc Robert's technique – flex knees to chest with pt on her back Suprapubic pressure Position mother on hands and knees with knees to chest Break clavicle if everything else fails (pinch midpoint of clavicle and snap it).
Cord Prolapse	Bluish gray cord of tissue in vagina	This can compress cord, causing decreased oxygen to baby when head engages. Needs surgical delivery. Tell mother to stop pushing, elevate hips, push head up. Give mother oxygen
Post Partum Haemorrhage	Bleeding after delivery	External massage of uterine fundus Inspect for tears Inspect placenta Bimanual compression oxytocin

SAQ 23 (11 marks)

You are the in charge consultant at an urban district hospital. You receive a batcall about a 2 year old who has been dragged unconscious from a backyard pool. It is the middle of winter.

His vital signs en route are:

HR	70	GCS	Unresponsive
BP	70/40	Temp	30 degrees
O2 sats 90% (bag valve mask FiO2 1.0)			

List 4 predictors of poor outcome in drowning (4 marks)

- i) Long immersion time > 10 mins
- ii) Delay to CPR
- iii) Time to first breath
- iv) Coma on arrival in ED
- v) Presence of cardiac arrest at scene
- vi) Water temperature – cold is more neuroprotective
- vii) Severe metabolic acidosis

You intubate this child on arrival. This is his initial CXR. List 2 relevant features at this stage of the patient's management (2 marks).

- i) Bilateral coalescing pulmonary infiltrates – concern for ARDS (must mention)
- ii) ETT appropriately placed

- iii) NGT below diaphragm - aspiration risk and affect on ventilation if GIT no decompressed

What ventilation strategies would you use (2 marks)

Low volume ventilation

ARDS ventilation

What are your other initial management priorities (3 marks)

- i) Protective lung ventilation strategies and maintenance of oxygenation

Justification: ARDS/ALI, VQ mismatch predicted given CXR, prevention of secondary brain injury from hypercarbia/hypoxia

- ii) Cardiovascular support and fluid resuscitation

Justification: hypovolaemia (from cold diuresis +/- hydrostatic pressure of water on the body following prolonged immersion) and arrhythmias predicted. Prevention of secondary brain injury from hypotension.

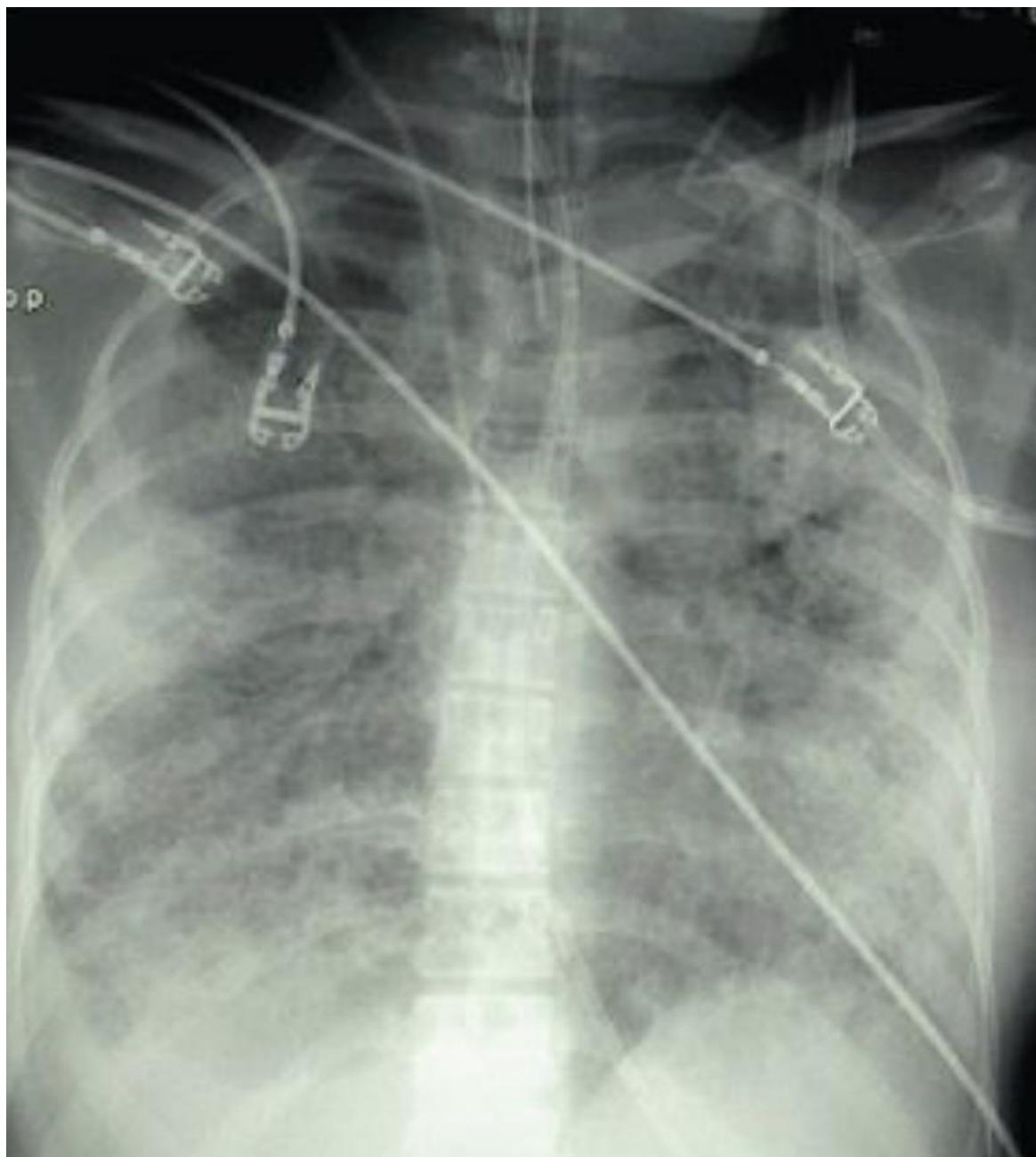
- iii) Rewarming to 34 degrees and prevention of shivering

Justification: To prevent organ/systemic complications of hypothermia - CNS/resp/metabolic/GI/haematological (coagulopathy).

- iv) Disposition planning and contacting retrieval services

Justification: Patient requires paediatric ICU management at a tertiary centre, may require haemodialysis/ECMO

SAQ 23 image



SAQ 24 (12 marks)

A 60 yr old man with a past history of type 2 diabetes, presents after being found on the floor by his elderly mother . He has recently been unwell with vomiting for the last 3 weeks. 12 marks

His vital signs are as follows :

BP 65/30 , GCS 13, pulse 120 regular, oxygen saturations 100% on 15 L NRM.

His arterial blood gas is attached.

Interpret the abnormalities in the above results (4 marks)

Severe metabolic acidosis

Some respiratory compensation (not fully compensated, expected CO₂ 13)

Hyperglycaemia , ?DKA

Renal impairment (Cr 246)

Severe metabolic acidosis , multifactorial : likely sec DKA, ARF .

How would you initially manage these abnormalities ? (3 marks)

IV fluid bolus -500ml – 1 L initially, then repeat as needed (note severe hypotension)

May need inotropic support

Insulin infusion 5 units/ hr, aim slow reduction of BSL

K⁺ replacement once K⁺ < 4

The patient's GCS deteriorates to 5 and he begins vomiting, what is your plan with regards to intubating this patient, and what ventilation strategy would you employ ? (5 marks)

- prepare for possible arrest
- have fluids and inotropes running prior to intubation
- most senior doctor intubating, video laryngoscopy if available
- drugs : ketamine 1mg/kg, suxamethonium
- high ventilation rate, as need to maintain low CO₂ to avoid worsening acidosis.

- early referral to ICU for management of ventilation on ICU ventilator.

SAQ 24 image

Arterial Blood pH POCT	L 6.865
Arterial Blood pO ₂ POCT	H 417.0 mmHg
Arterial Blood pCO ₂ POCT	L 18.7 mmHg
Arterial Blood O ₂ Saturation POCT	99.2 %
Arterial Blood HCO ₃ POCT	L 3.2 mmol/L
Arterial Blood Base Excess POCT	L -27.2 mmol/L
Arterial Blood Oxyhaemoglobin POCT	97.2 %
Arterial Blood Inspired Oxygen POCT	100 %
Arterial Blood Haemoglobin POCT	L 124 g/L
Arterial Blood Reduced Haemoglobin POCT	0.8 %
Arterial Blood Methaemoglobin POCT	H 0.9 %
Arterial Blood Carboxyhaemoglobin POCT	1.1 %
Arterial Blood Creatinine POCT	H 246 umol/L
Arterial Blood Sodium POCT	142 mmol/L
Arterial Blood Potassium POCT	4.6 mmol/L
Arterial Blood Chloride POCT	107 mmol/L
Arterial Blood Calcium Ionised POCT	1.30 mmol/L
Arterial Blood Glucose POCT	H 31.0 mmol/L
Arterial Blood Lactate POCT	L 1.7 mmol/L

SAQ 25 (14 marks)

A 34 year old man presents 10 days after a business trip to Papua New Guinea. He has had fevers, malaise, generalised aches and frequent episodes of diarrhoea. HR 130 BP 100/50 Temp 38 Sats 98% on air.

List 10 potential causes of fever & illness in this man (5 marks)

Malaria

Dengue

Typhoid/paratyphoid

GIT infections – cholera, shigella, salmonella, E coli diarrhoea, giardiasis etc

Viral hepatitis

Typhus/rickettsial diseases

Melioidosis

Japanese or Australian (Murray Valley) encephalitis

Non-exotic/"normal" infections – LRTI, UTI, STI, cellulitis etc etc etc

What blood tests will you request? (3 marks)

Investigation	Justification
FBC	Part of fever workup. ?malaria → anaemia
EUC	Unwell, diarrhoea → potential derangement
LFT	Hepatitis possible
Blood culture	Part of workup
Malaria films	Ideally 3 sets over 48 hours (practice varies)
Falciparum +/- vivax antigen	> 95% sensitive for PF

List 4 major complications of severe Plasmodium falciparum malaria. (4 marks)

Haemolysis/anaemia

Splenic enlargement/rupture

Cerebral malaria – delirium, coma, seizures

ARF

Non-cardiogenic pulmonary oedema

Hypoglycaemia

Lactic acidosis

What are the two main choices for the urgent initial treatment of severe Plasmodium falciparum malaria? (2 marks)

1. Artesunate (2.4mg/kg IV) then oral
2. Quinine (20mg/kg IVI over 4 hours)

SAQ 26 (12 marks)

A 32 yr old Aboriginal woman presents to the ED with lethargy. She is previously well, and has not been seen by medical services for the previous 10 yrs,

Her VBG is attached.

What is the most likely cause for the abnormalities on the VBG ? Describe and interpret the abnormalities (5 marks)

Table might look something like this:

pH	Compensated metabolic acidosis. Expected $pCO_2 = 8 + (1.5 \times 12) = 26$ (about right) Anion gap = 30 – profoundly raised Delta ratio = $AG - 12 / 24 - HCO_3 = 18 / 12 = 1.5 = RAGMA$ i.e widened anion gap probably from uraemia (consider ketosis)
K	Mild hyperkalaemia ?artefactual/ ?renal failure
GLuc	Mild hyperglycaemia from untreated DM
Ca	Hypocalcaemia from renal failure
Hb	Anaemia would be consistent with renal failure ? other causes/ acute blood loss etc
Summary	Most likely cause is renal failure with uraemia, hyperkalaemia, hypocalcaemia and anaemia. In the setting of untreated diabetes.

Her creatinine is 1842 with a urea of 62

List 4 possible causes for these findings in a 32 yr old Aboriginal woman, with the most common cause first. (3 marks)

(3 points; at least one bold to pass)

Post strep GN
DMII nephropathy
Other forms of GN
Causes of ARF

She becomes agitated and appears to be getting ready to leave the ED. What would be some strategies to stop her leaving ? (4 marks)

(4 points; bold required, need at least 3)

Get ALO/ILO
Create rapport by asking where she is from, introducing oneself
Explore: try to find why she wants to leave, can we assist with that, what are her concerns, what is her understanding of what is going on
Appropriate body language
Do not force eye contact
Gender preference for doctor

SAQ 26 image

pH	7.25
pCO ₂	24.4
HCO ₃	11.7
Hb	81
Na	140
K	5.1
Ca ⁺⁺	0.81
Cl	98
Gluc	9.6
Lact	0.9